

# Development of the Nervous System and Special Senses

## Neurulation

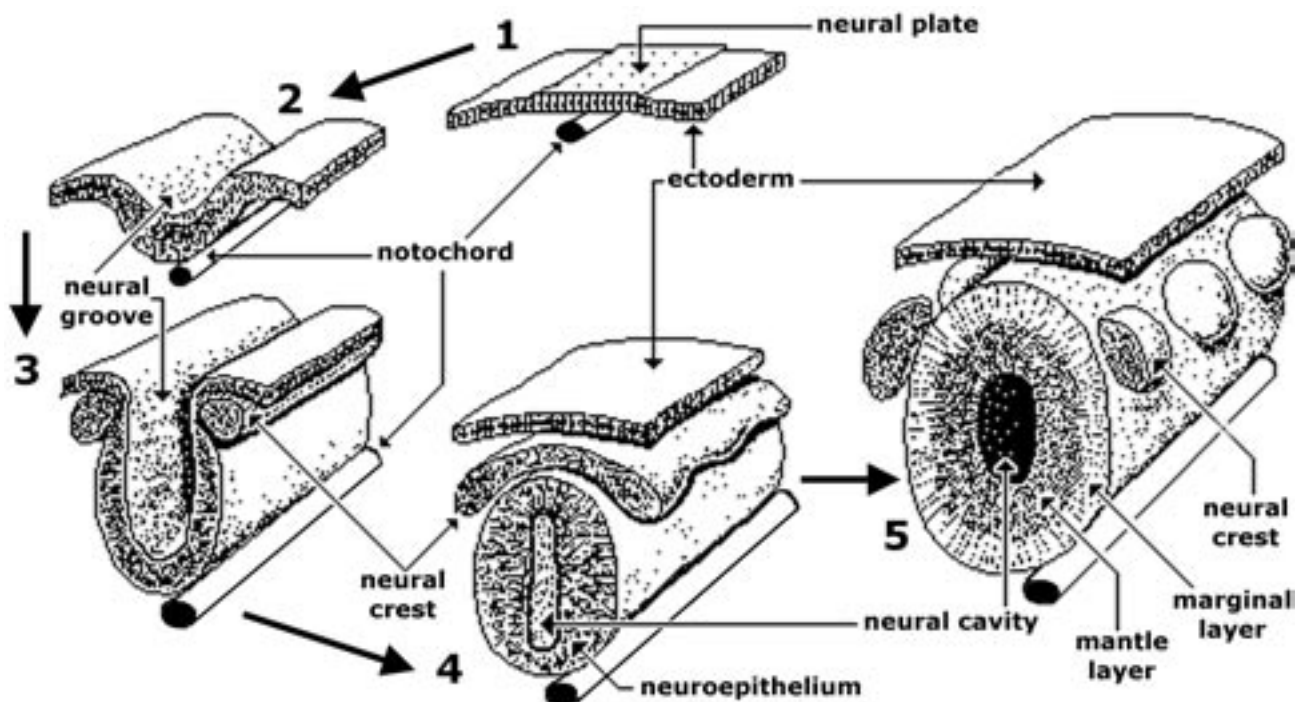
The notochord induces overlying ectoderm to become neuroectoderm and form a neural tube. The following stages of neural tube formation are evident:

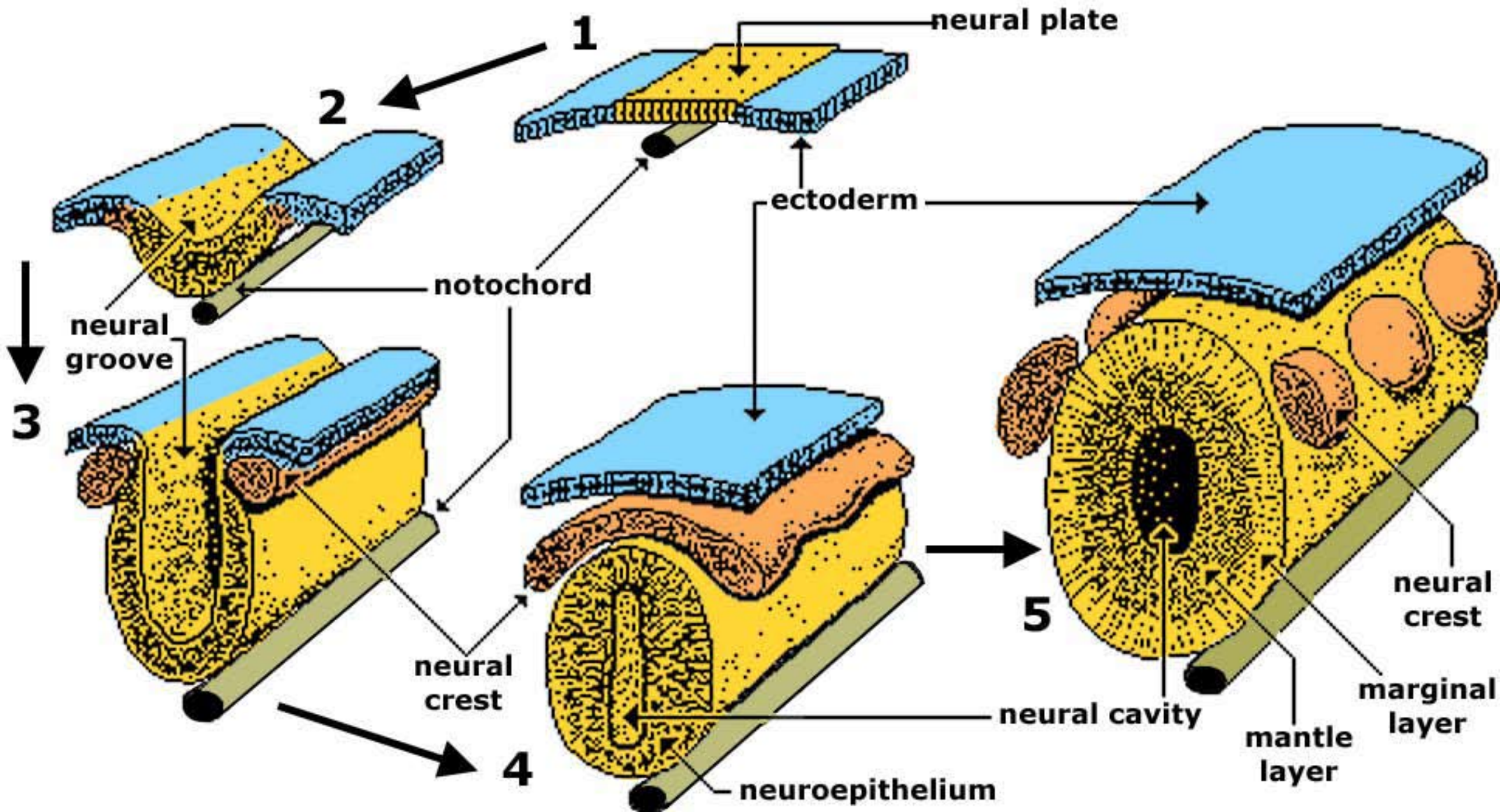
- **neural plate**—ectodermal cells overlying the notochord become tall columnar, producing a thickened neural plate (in contrast to surrounding ectoderm that produces epidermis of skin).
- **neural groove**—the neural plate is transformed into a neural groove.
- **neural tube**—the dorsal margins of the neural groove merge medially, forming a neural tube composed of columnar neuroepithelial cells surrounding a **neural cavity**.

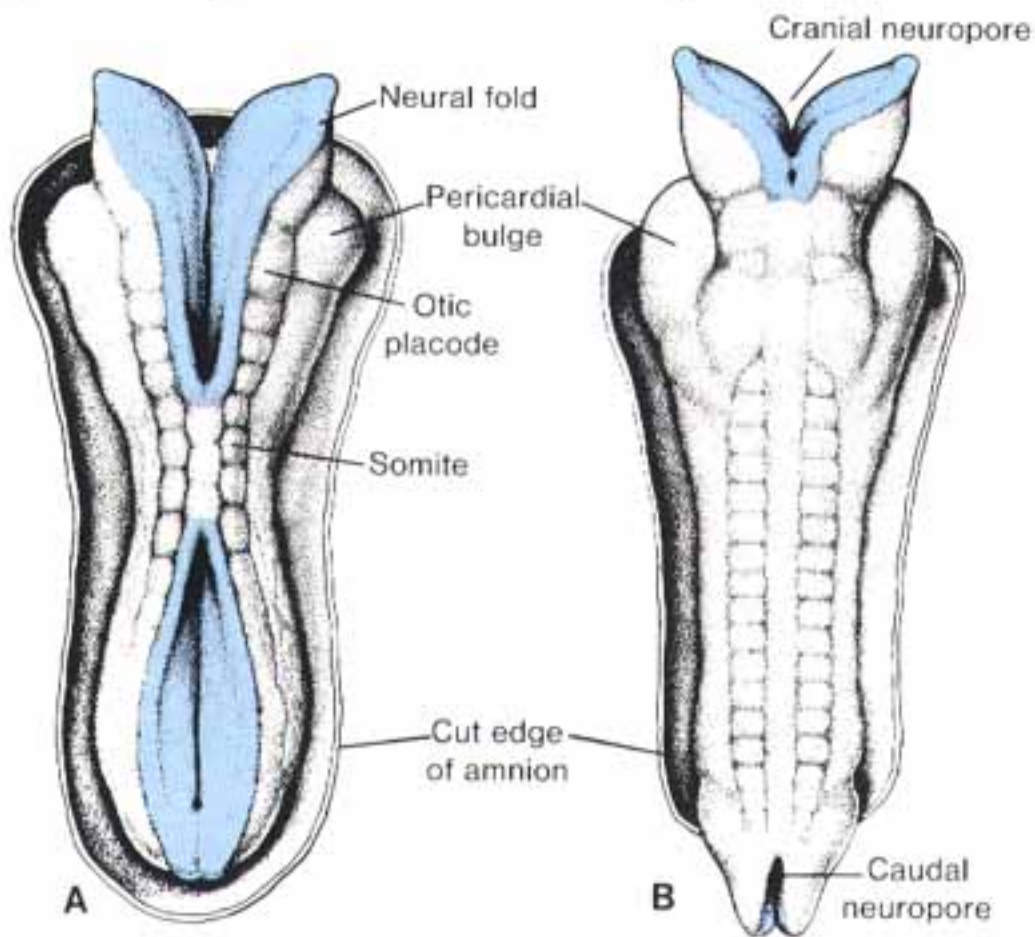
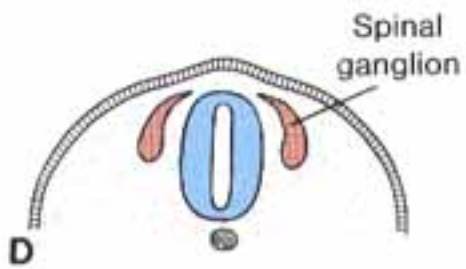
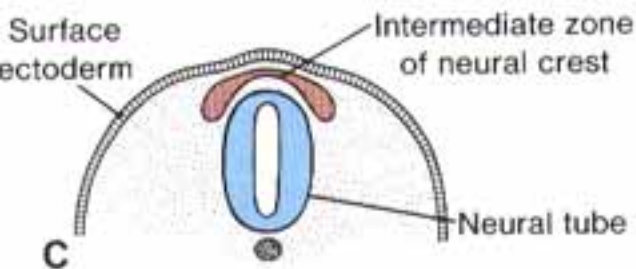
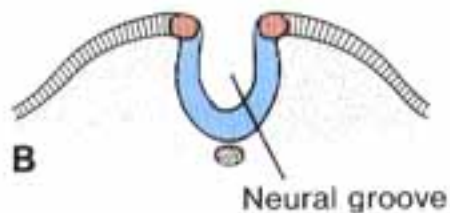
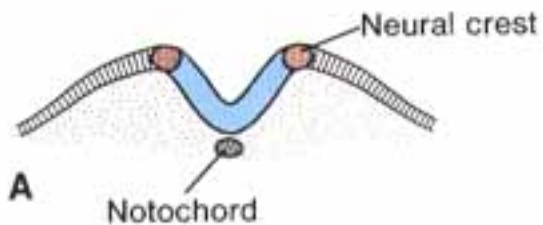
In the process of separating from overlying ectoderm, some neural plate cells become detached from the tube and collect bilateral to it, forming **neural crest**.

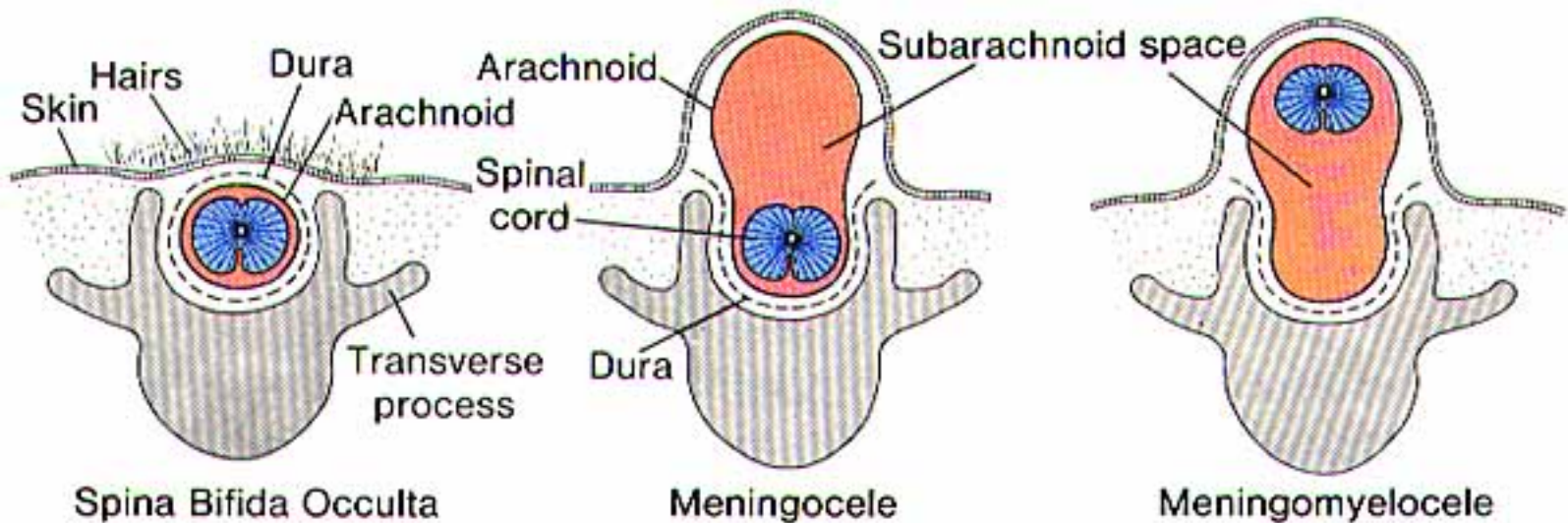
*Note:*

- **Neural tube** becomes central nervous system (CNS), which consists of the brain and spinal cord. The cavity of the tube (neural cavity) becomes the ventricles of the brain and central canal of the spinal cord.
- **Neural crest** cells become those neurons of peripheral nervous system (PNS) that have their cell bodies located in ganglia. They also become neurolemmocytes (Schwann cells) of the PNS. Additionally, neural crest cells become adrenal medulla cells, melanocytes of skin and a variety of structures in the face.

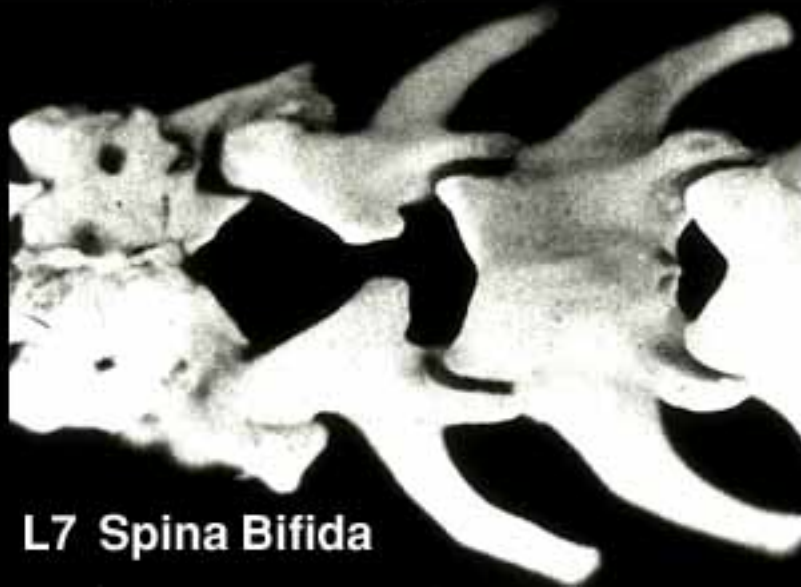







## Types of Spina Bifida



# Central Nervous System

## Formation of neurons and glial cells from neuroepithelium:

Neuroepithelium gives rise to neurons, glial cells (astrocytes and oligodendrocytes), and ependymal cells (additionally, the CNS contains blood vessels and microglial cells derived from mesoderm).

Neuroepithelial cells have processes which contact the inner and outer surfaces of the neural tube; they undergo mitotic division in the following manner:

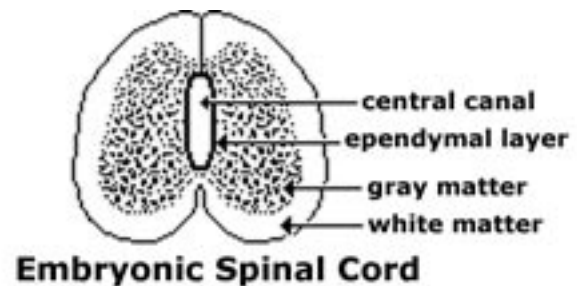
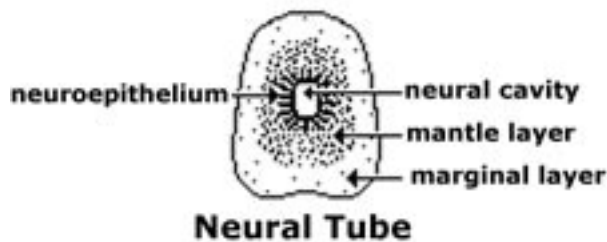
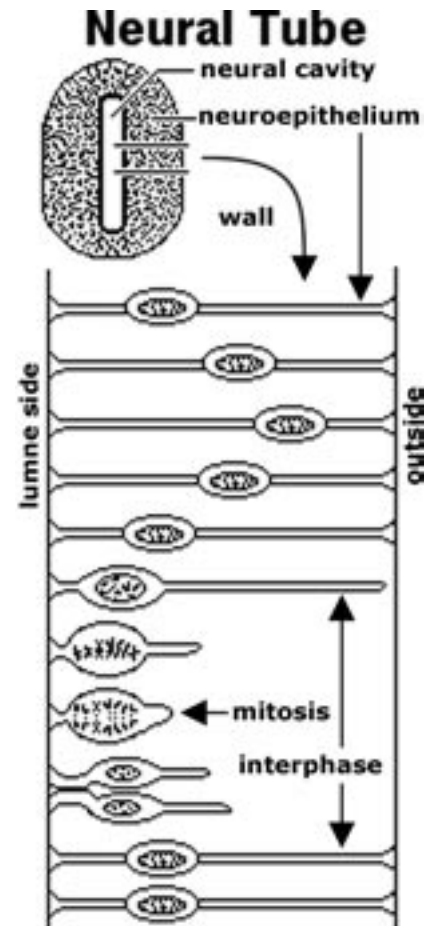
- the nucleus (and perikaryon) moves away from the neural cavity for interphase (DNA synthesis);
- the nucleus moves toward the neural cavity and the cell becomes spherical and loses its connection to the outer surface of the neural tube for mitosis; this inward-outward nuclear movement is repeated at each cell division.

Some cell divisions are differential, producing neuroblasts which give rise to neurons or glioblasts (spongioblasts) which give rise to glial cells (oligodendroglia and astrocytes). Neuroblasts and glioblasts lose contact with surfaces of the neural tube and migrate toward the center of the neural tube wall.

Note: Microglia are derived from mesoderm associated with invading blood vessels.

## Layers and plates of the neural tube:

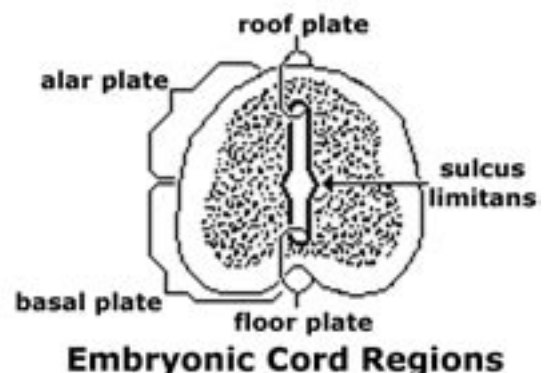
Accumulated neuroblasts and glioblasts form the mantle layer, a zone of high cell density in the wall of the neural tube. Cells that remain lining the neural cavity are designated ependymal cells; they form an ependymal layer. Surrounding the mantle layer, a cell-sparse zone where axons of neurons and some glial cells are present is designated the marginal layer. The mantle layer becomes gray matter and the marginal layer becomes white matter of the CNS.

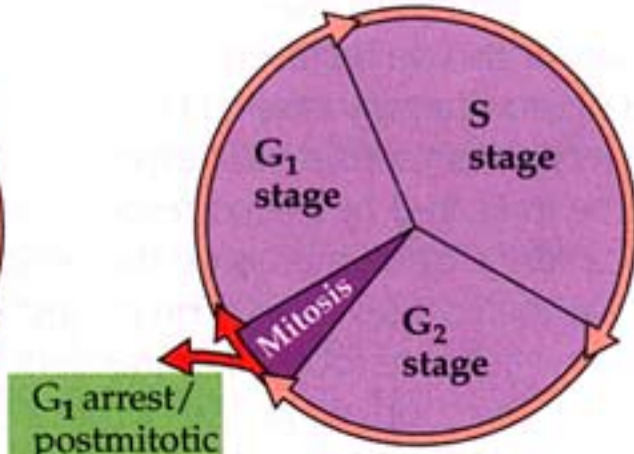
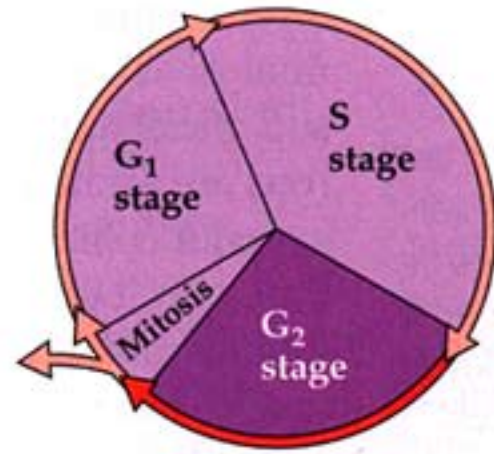
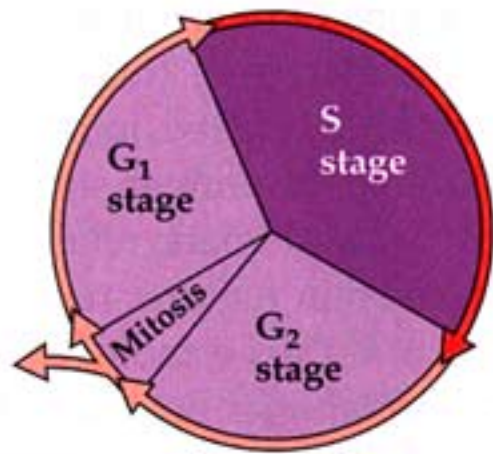
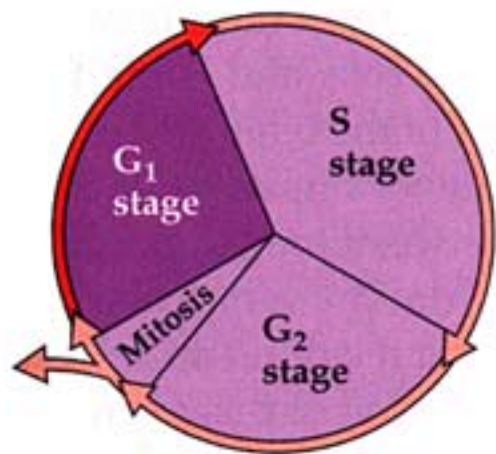


The lateral wall of the neural tube is divided into two regions (plates). A bilateral indentation evident in the neural cavity (the *sulcus limitans*) serves as a landmark to divide each lateral wall into an *alar plate* (dorsal) and a *basal plate* (ventral). Midline regions dorsal and ventral to the neural cavity constitute, respectively, the *roof plate* and the *floor plate*.

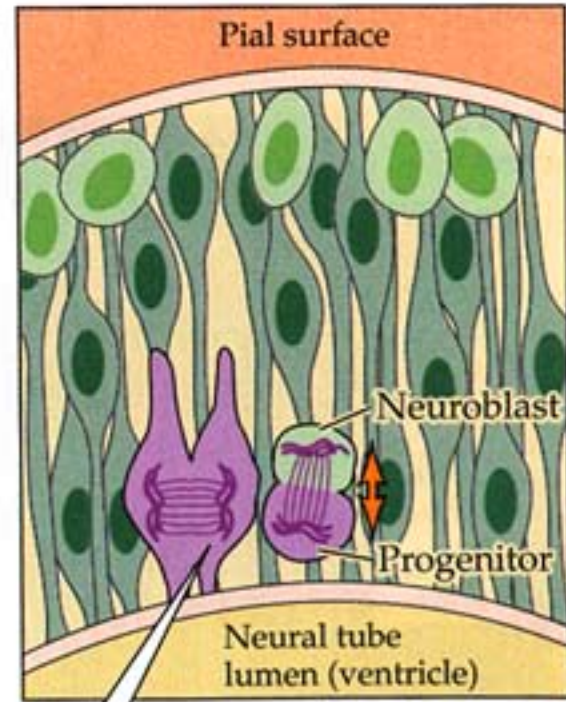
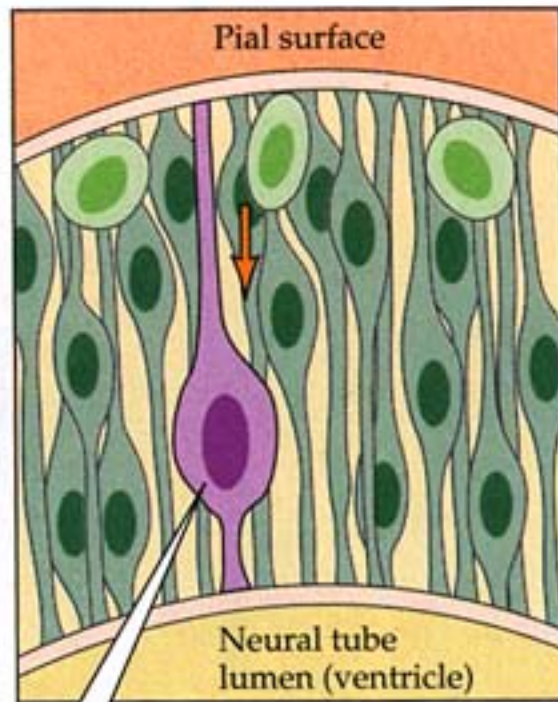
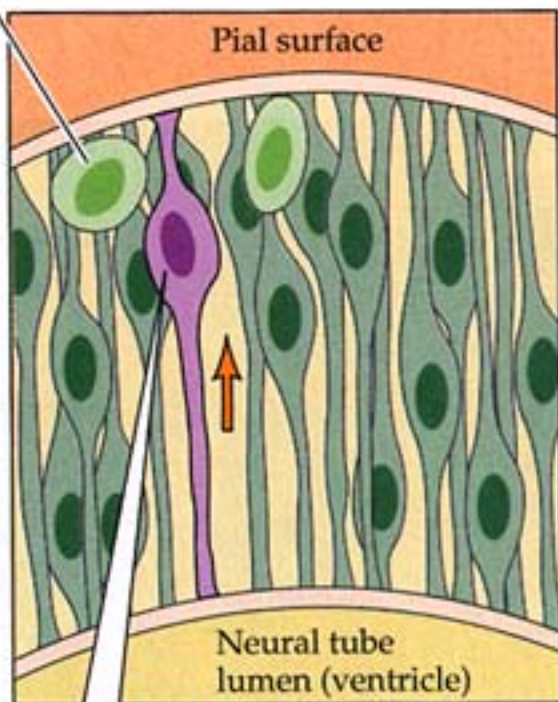
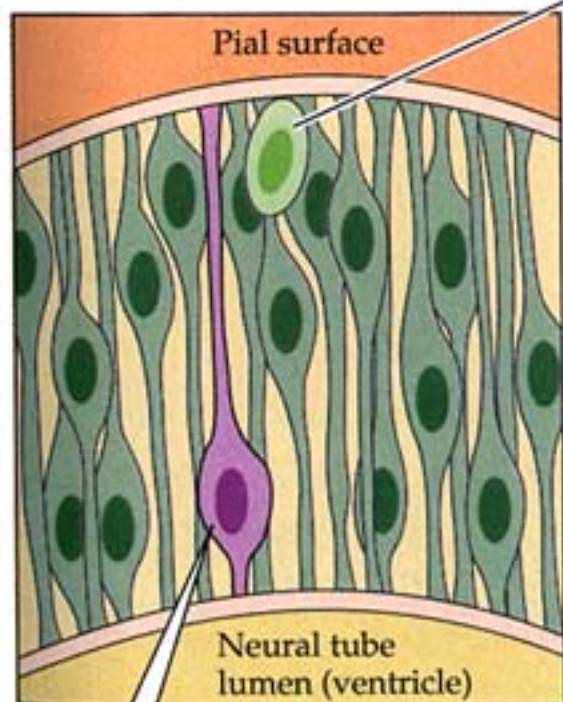
The basal plate contains efferent neurons that send axons into the PNS.

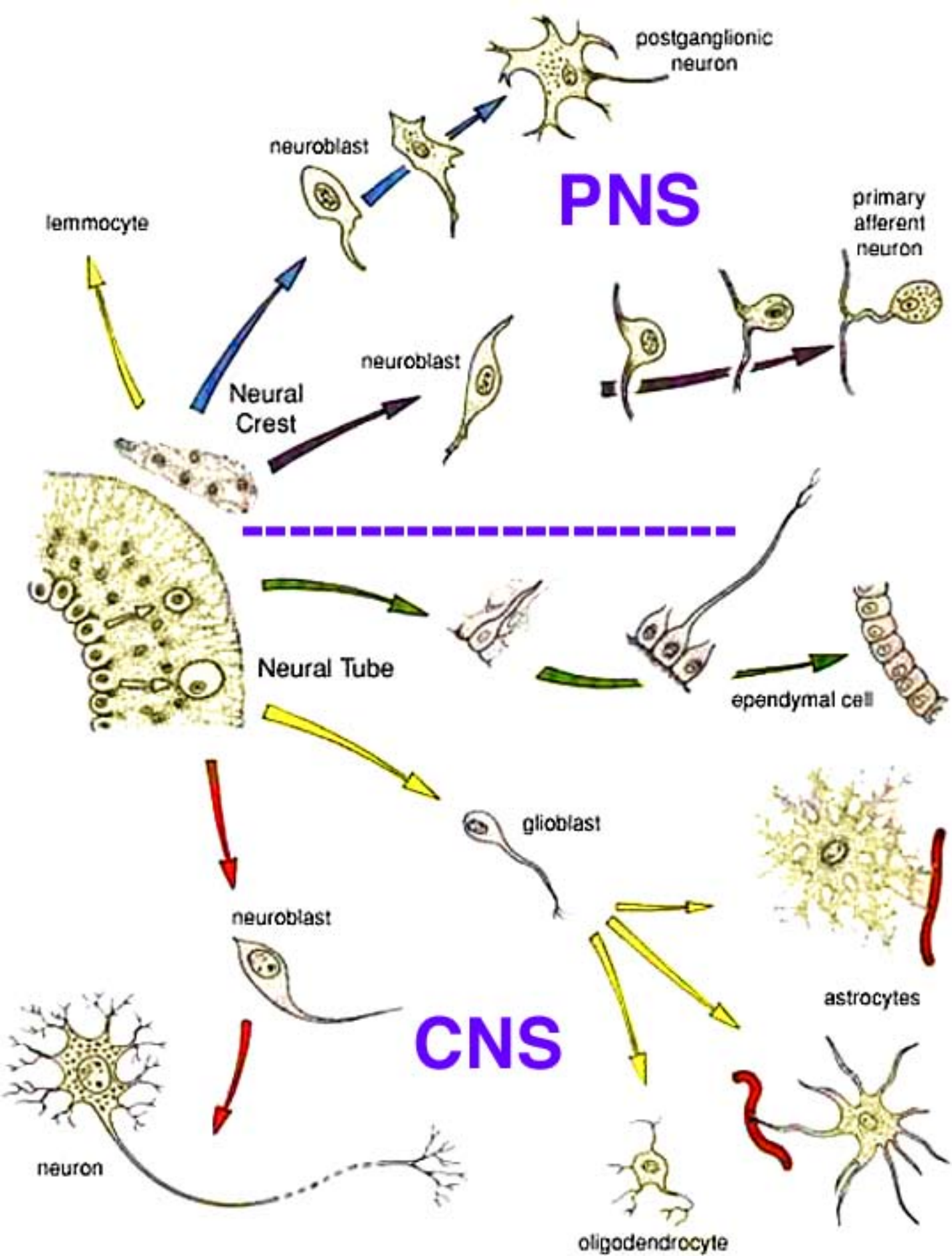
The alar plate contains neurons that receive input from the PNS.





Postmitotic neuroblasts





# Central Nervous System

## Formation of neurons and glial cells from neuroepithelium:

Neuroepithelium gives rise to neurons, glial cells (astrocytes and oligodendrocytes), and ependymal cells (additionally, the CNS contains blood vessels and microglial cells derived from mesoderm).

Neuroepithelial cells have processes which contact the inner and outer surfaces of the neural tube; they undergo mitotic division in the following manner:

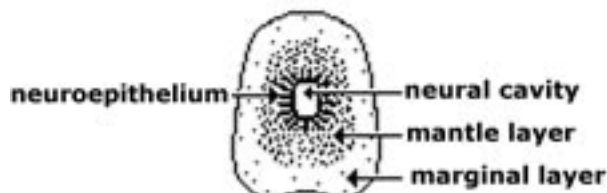
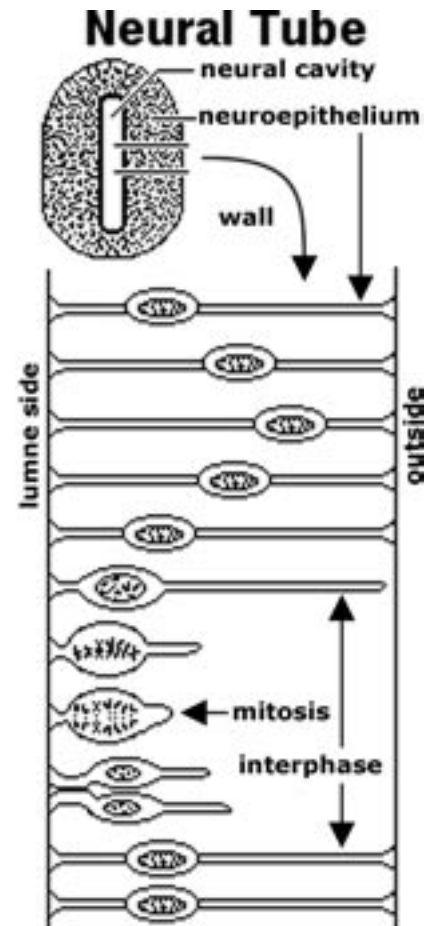
- the nucleus (and perikaryon) moves away from the neural cavity for interphase (DNA synthesis);
- the nucleus moves toward the neural cavity and the cell becomes spherical and loses its connection to the outer surface of the neural tube for mitosis; this inward-outward nuclear movement is repeated at each cell division.

Some cell divisions are differential, producing neuroblasts which give rise to neurons or glioblasts (spongioblasts) which give rise to glial cells (oligodendrocytes and astrocytes). Neuroblasts and glioblasts lose contact with surfaces of the neural tube and migrate toward the center of the neural tubewall.

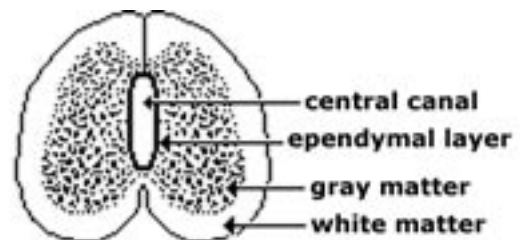
Note: Microglia are derived from mesoderm associated with invading blood vessels.

## Layers and plates of the neural tube:

Accumulated neuroblasts and glioblasts form the mantle layer, a zone of high cell density in the wall of the neural tube. Cells that remain lining the neural cavity are designated ependymal cells; they form an ependymal layer. Surrounding the mantle layer, a cell-sparse zone where axons of neurons and some glial cells are present is designated the marginal layer. The mantle layer becomes gray matter and the marginal layer becomes white matter of the CNS.



**Neural Tube**

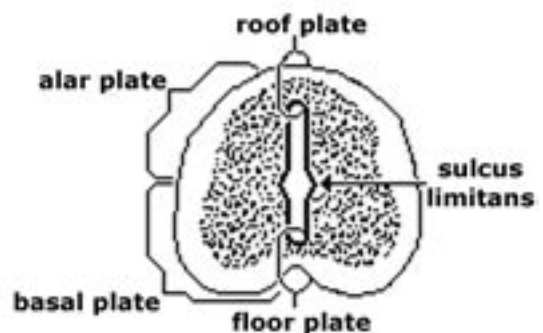


**Embryonic Spinal Cord**

The lateral wall of the neural tube is divided into two regions (plates). A bilateral indentation evident in the neural cavity (the *sulcus limitans*) serves as a landmark to divide each lateral wall into an *alar plate* (dorsal) and a *basal plate* (ventral). Midline regions dorsal and ventral to the neural cavity constitute, respectively, the *roof plate* and the *floor plate*.

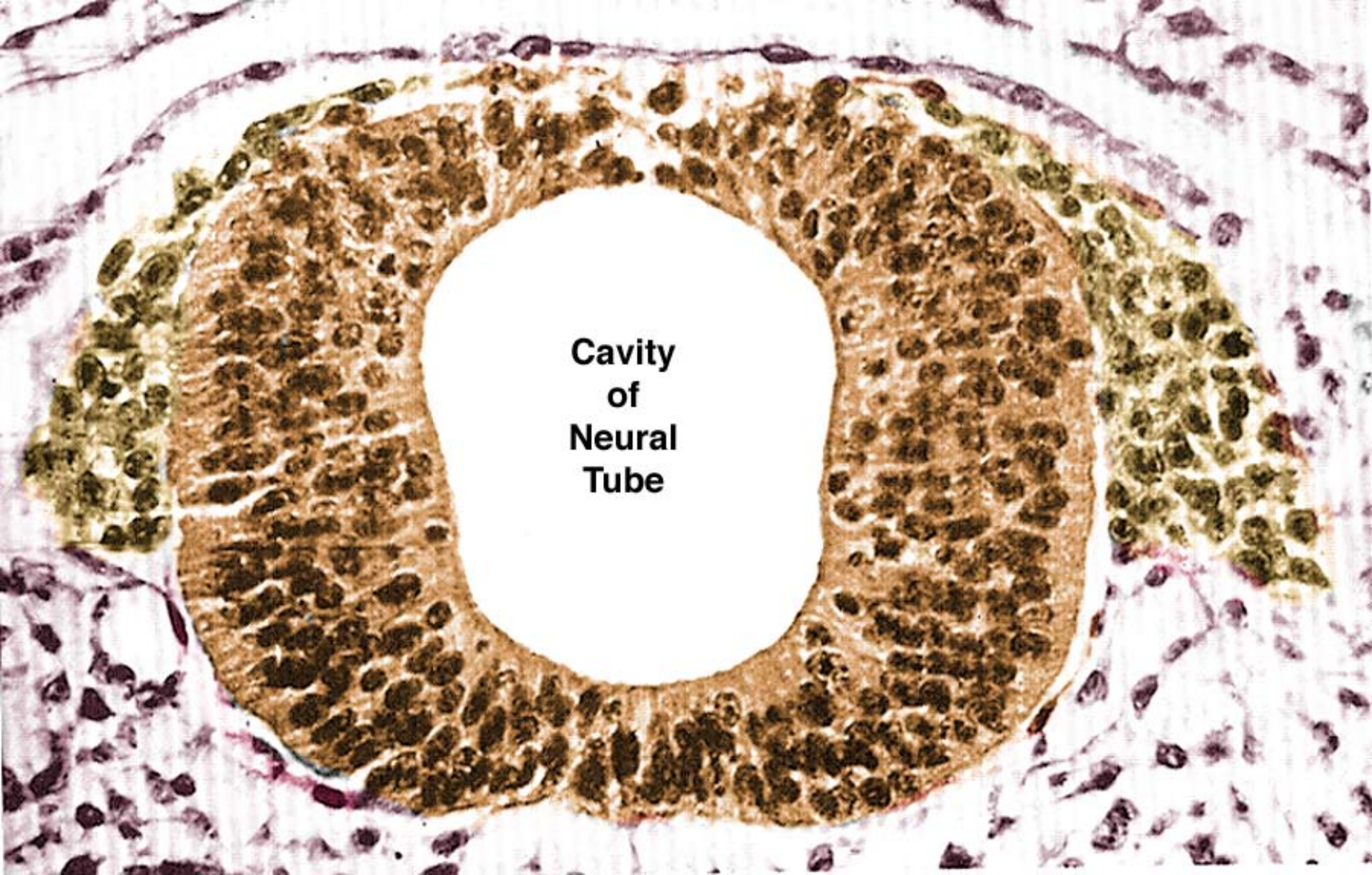
The basal plate contains efferent neurons that send axons into the PNS.

The alar plate contains neurons that receive input from the PNS.

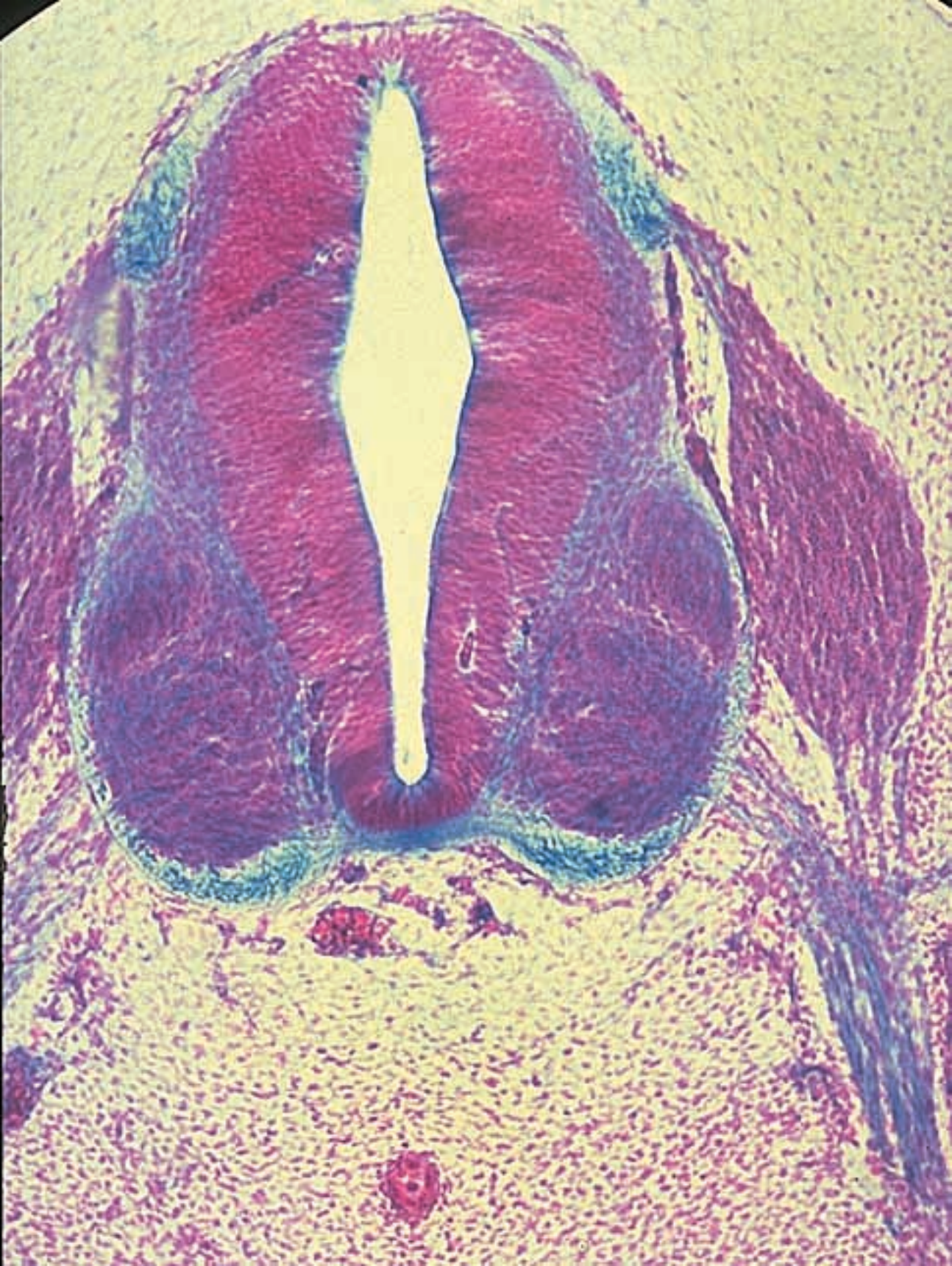

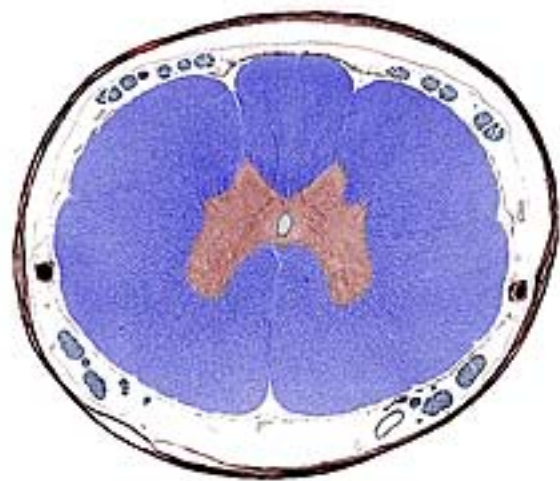
**Embryonic Cord Regions**



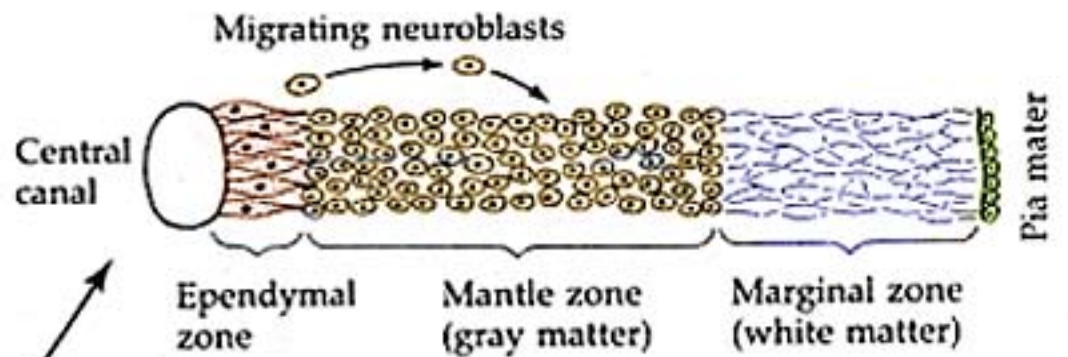


**Cavity  
of  
Neural  
Tube**



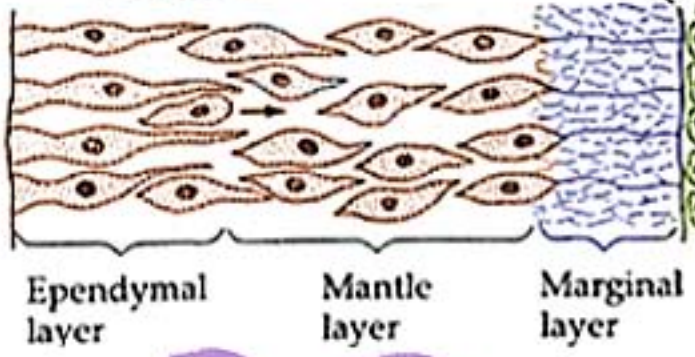


# Spinal Cord

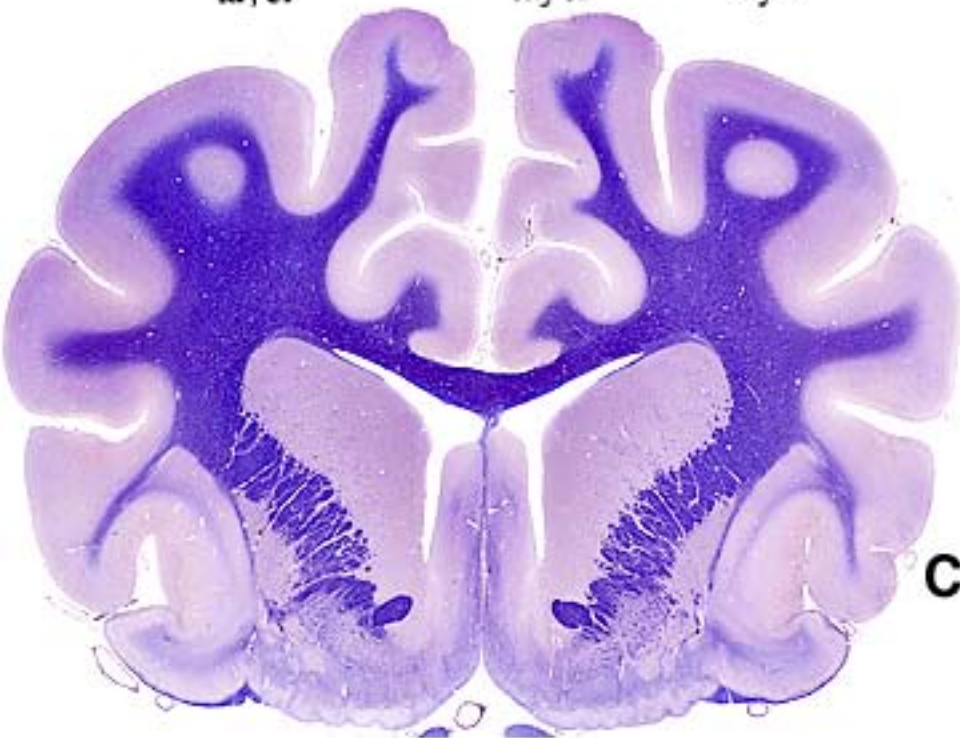
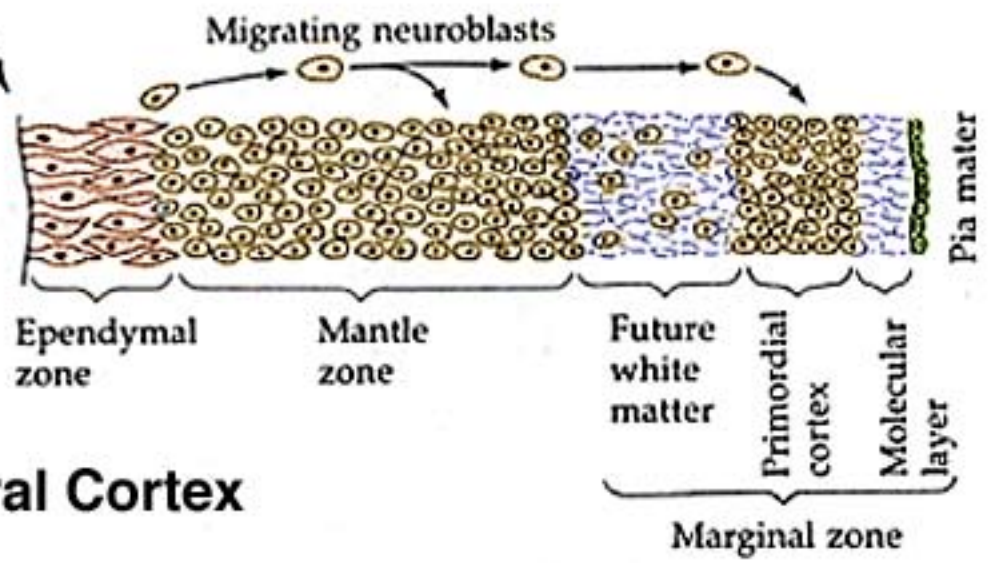


External limiting membrane  
Pial cell

Internal limiting membrane



# Mantle Cell Migrations



# Cerebral Cortex

Generally, neurons are incapable of cell division, so all neurons must be formed during nervous system development. However, in hippocampus and olfactory bulb, some stem cells or neuroblasts persist and can give rise to a small number of new neurons postnatally.

*Note:* • A typical neuron has a cell body (perikaryon) and numerous processes emanating from the cell body. One process, the axon, is generally long and often encased in a *myelin sheath* formed by glial cells. Unstained myelin has a white “color”.  
• *White matter* refers to CNS regions that have a high density of myelinated axons. *Gray matter* has sparse myelinated axons and generally a high density of neuron cell bodies.

## Sculpting Neuronal Circuits

*Sculpting – removing excess material to achieve a desired effect*

To ensure that all targets get sufficient innervation, initial neural development produces an excessive number of neurons along with a profuse, random growth of neuronal processes.

Neurons that fail to contact an appropriate target will degenerate and disappear, because they do not receive sufficient neurotrophic molecules. For the same reason, processes of surviving neurons will undergo degeneration if they fail to contact an appropriate target (selective pruning). Neurotrophic molecules are released by target cells to nurture neurons (and by neurons to modify target cells).

Selective degeneration of neurons and neuronal processes is the result of functional competition. More appropriate targets are associated with more excitation conduction and more neurotransmitter release. Thus developmental remodeling is a consequence of electrochemical activity related to experiences/behavior. **Throughout life, experiences drive nervous system remodeling through selective growth and pruning of neuronal synapses.**

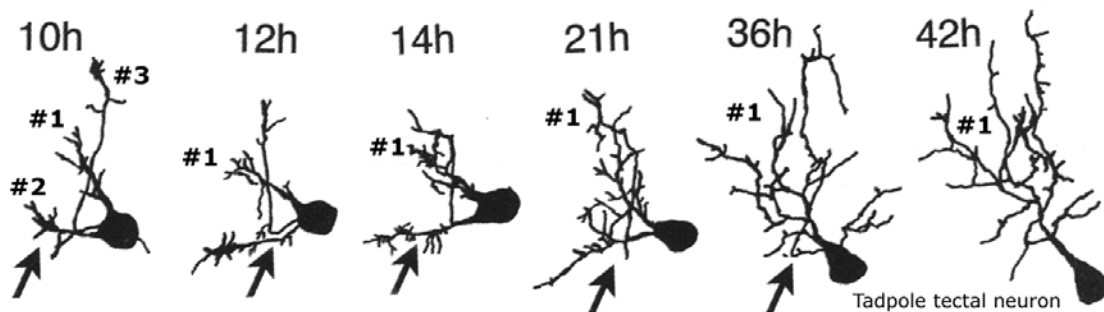
### *Neuromuscular Innervation*

Initially, individual neurons innervate an excessive number of muscle fibers and individual muscle fibers are innervated by a number motor neurons. Ultimately, motor neurons will innervate only about 10% of their initial muscle fibers and individual muscle fibers will retain only a single neuromuscular synapse.

The survivors (winners) released more neurotransmitter per terminal branch. (Neurons having fewer branches are able to release more neurotransmitter per terminal branch, giving them a competitive advantage over neurons with many more processes.)

### *Neonatal Cortex*

In human prefrontal cortex, synaptic density peaks during the first year of age (80K/neuron). The adult has half that synaptic density (and synaptic spine density). (Note: different studies show different timelines for degeneration of neurons and dendrites.)



# Nervous System Development

ectoderm stem cells



neuroectoderm stem cells



regional neural stem cells



**neuroblasts**



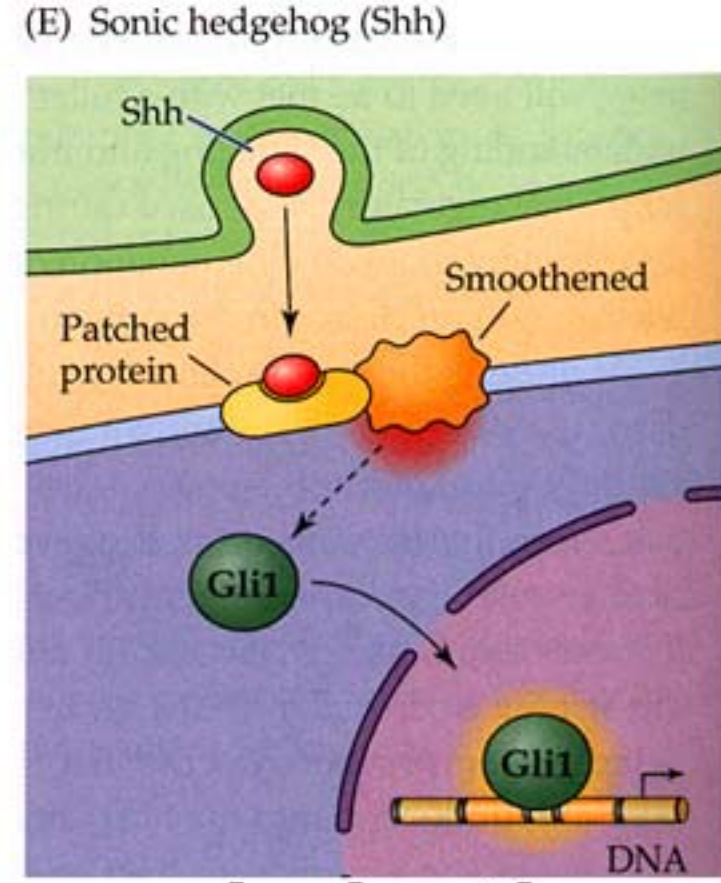
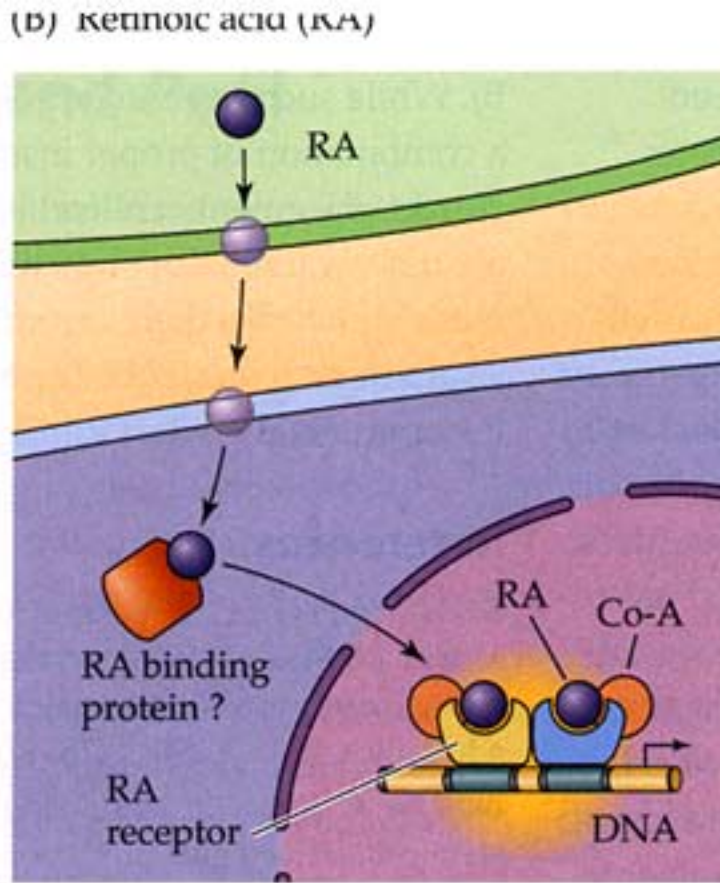
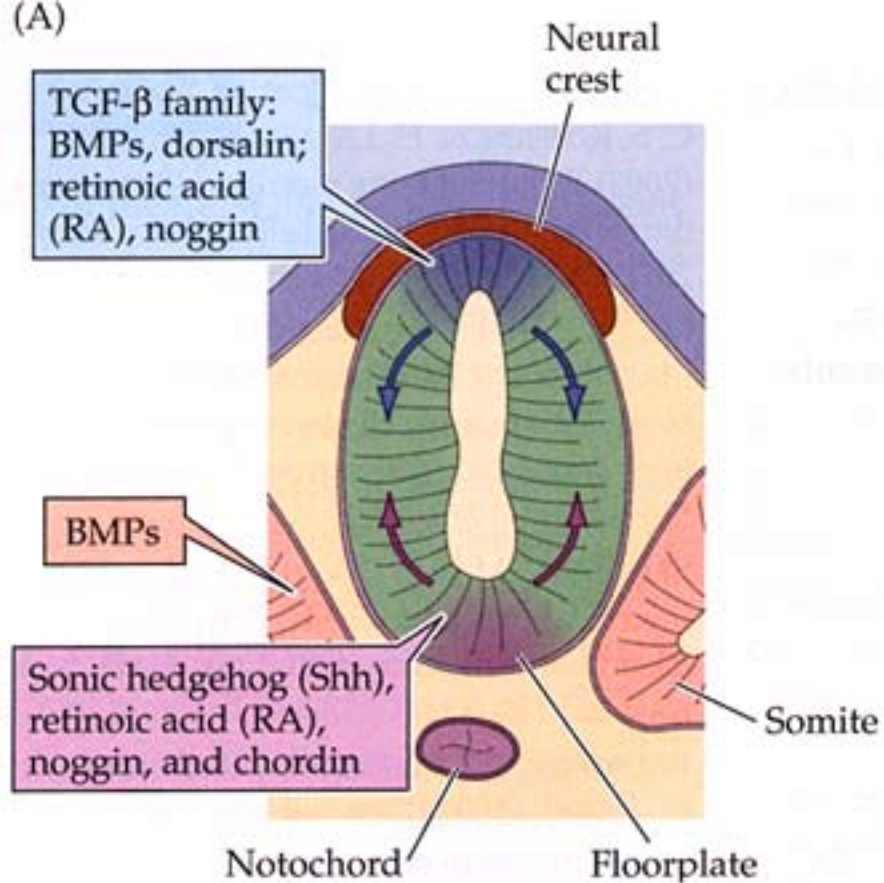
*neuroblast over-abundance  
driven by inducer gradients  
and stem cell proliferation*

*cannot divide — but can migrate  
cell processes find innervation targets  
must compete for trophic molecules*

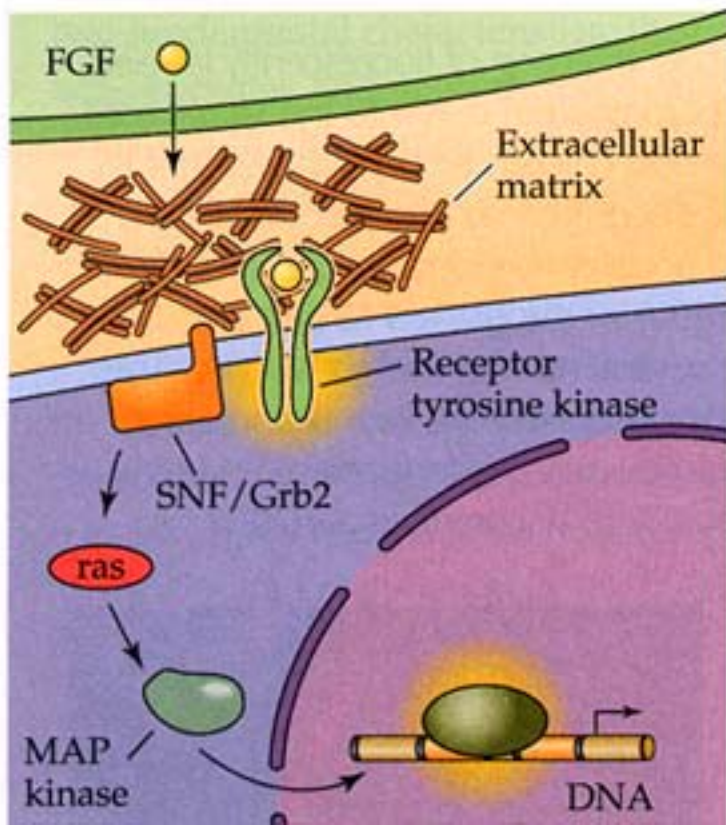
*cell death caused by  
failure to find targets  
and obtain trophic signals*

*differentiation into mature neurons  
requires cell to cell interaction  
driving gene expression*

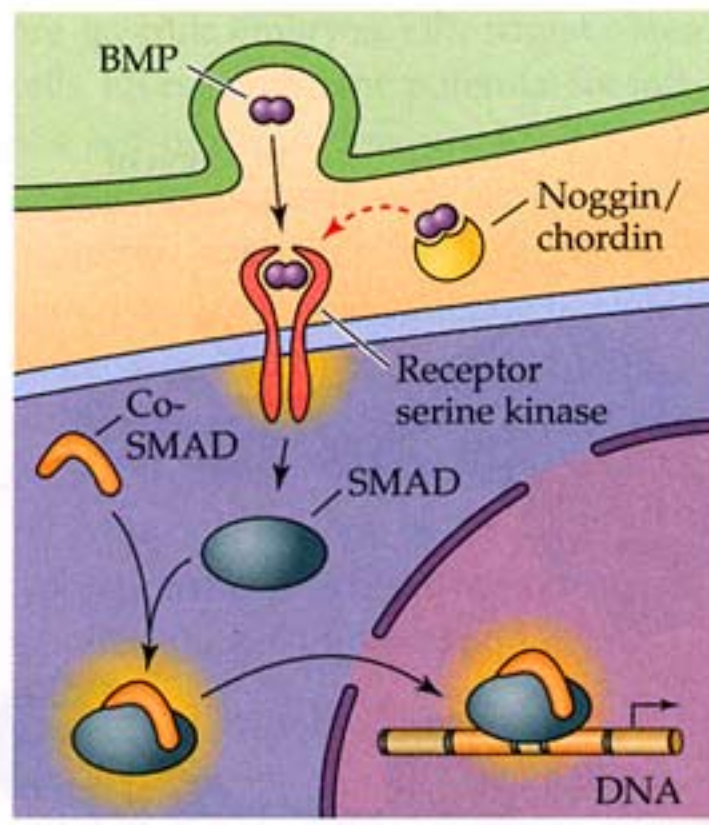
**functional neuron within a neural circuit**  
(neuron morphology / transmitter synthesis / membrane receptors)



(C) Fibroblast growth factor (FGF)

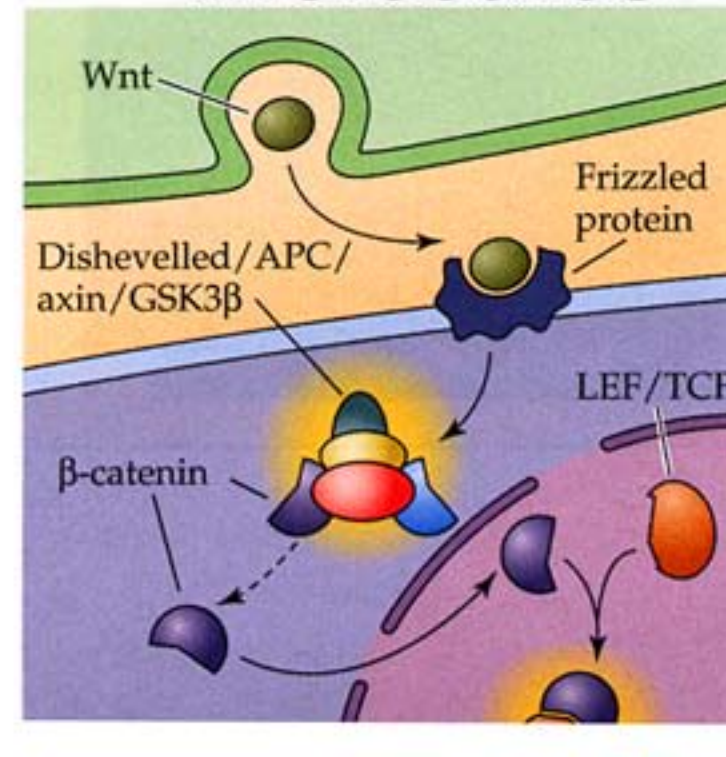


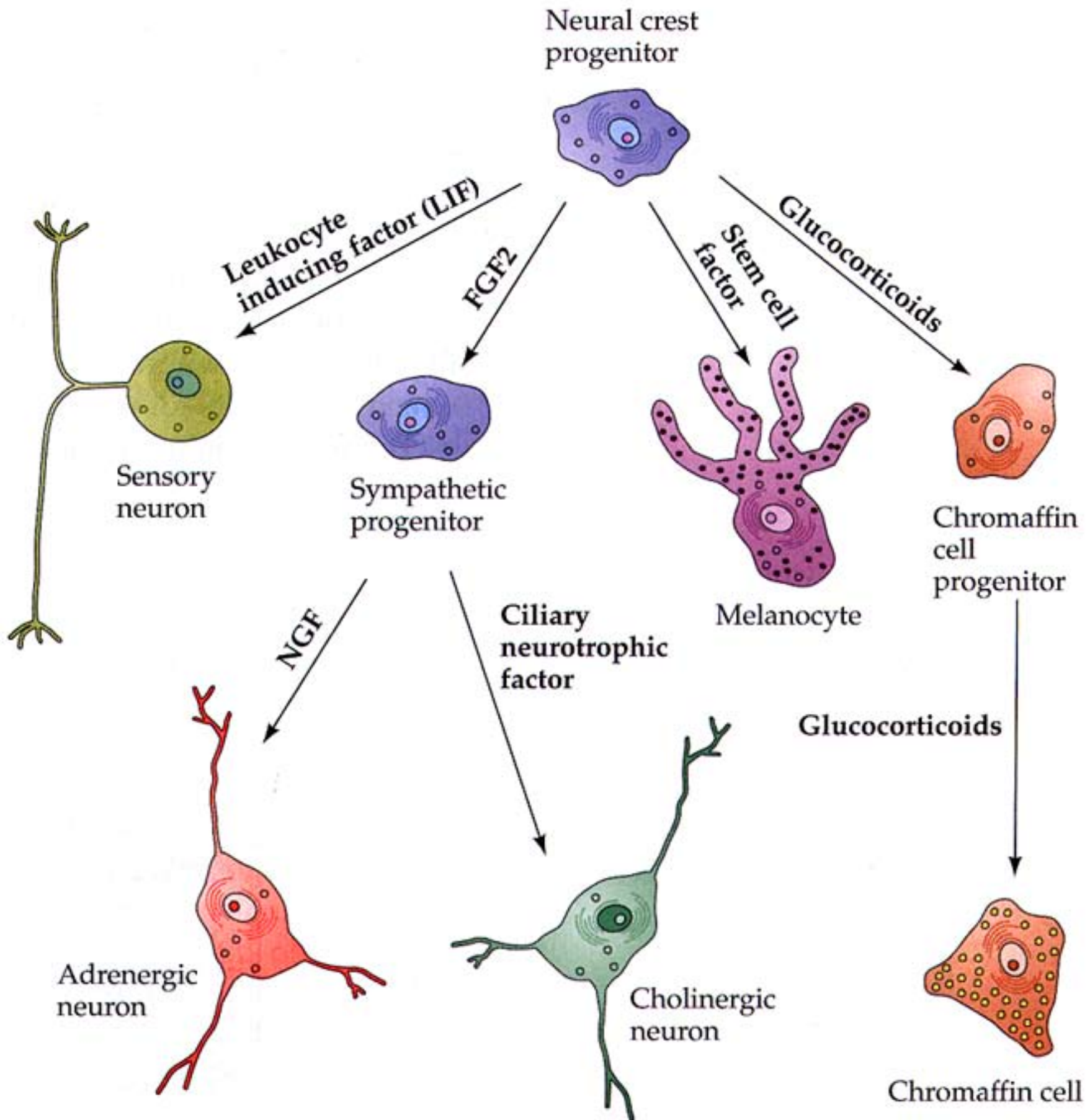
(D) Bone morphogenetic protein (BMP)



(F) Wnt

# Induction Molecules





## Formation of the Central Nervous System

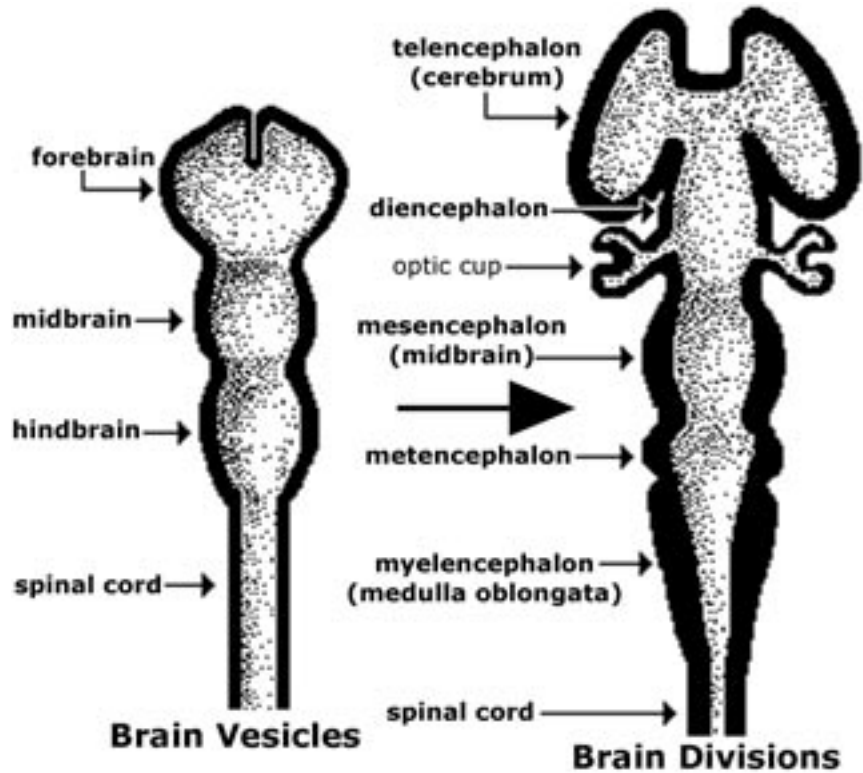
The cranial end of the neural tube forms three vesicles (enlargements) that further divide into the five primary divisions of the *brain*. Caudal to the brain the neural tube develops into *spinal cord*.

*Flexures*: During development, the brain undergoes three flexures which generally disappear (straighten out) in domestic animals.

The *midbrain flexure* occurs at the level of the midbrain.

The *cervical flexure* appears at the junction between the brain and spinal cord (it persists slightly in domestic animals).

The *pontine flexure* is concave dorsally (the other flexures are concave ventrally).

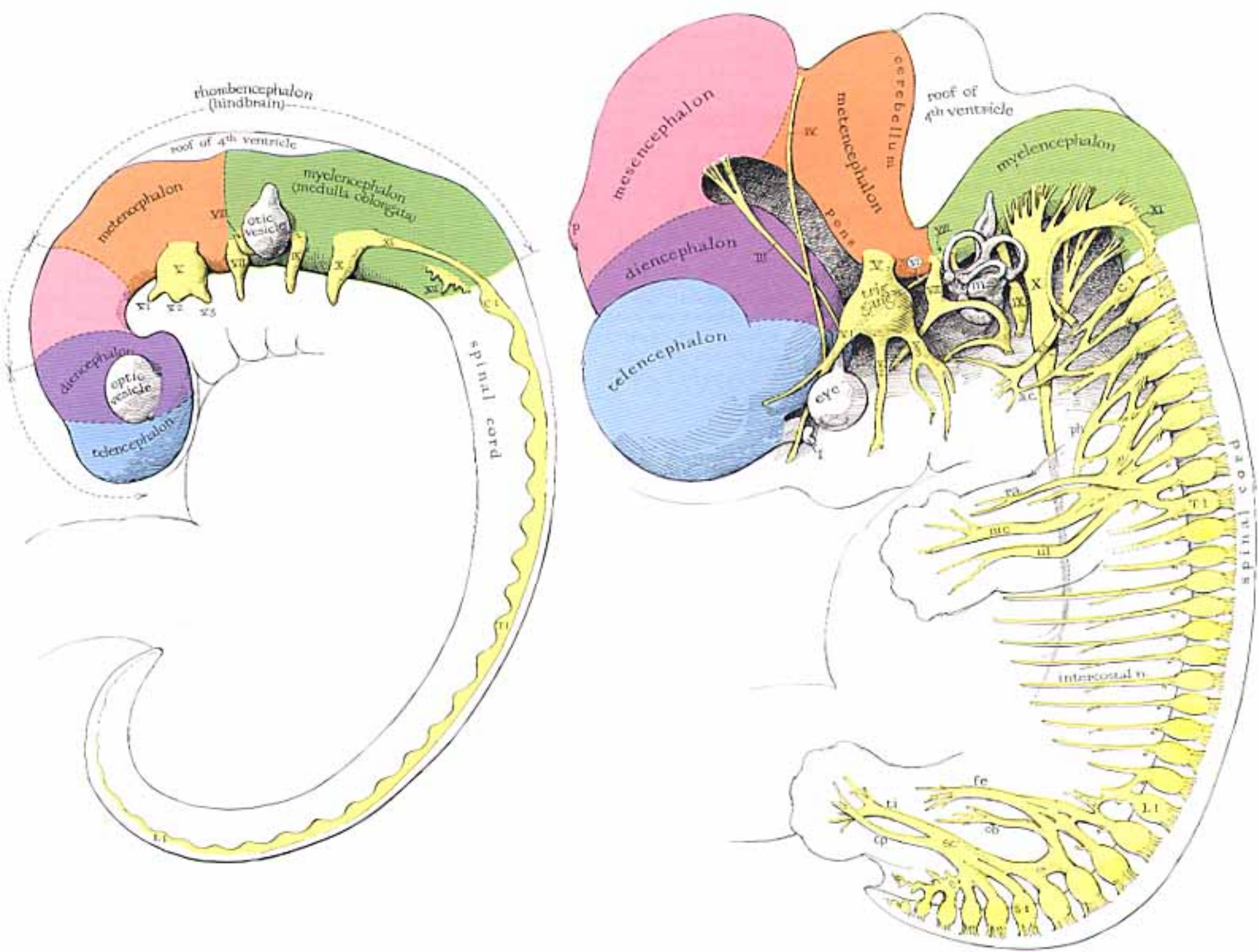


### Adult CNS Structures Derived From Embryonic Brain Divisions

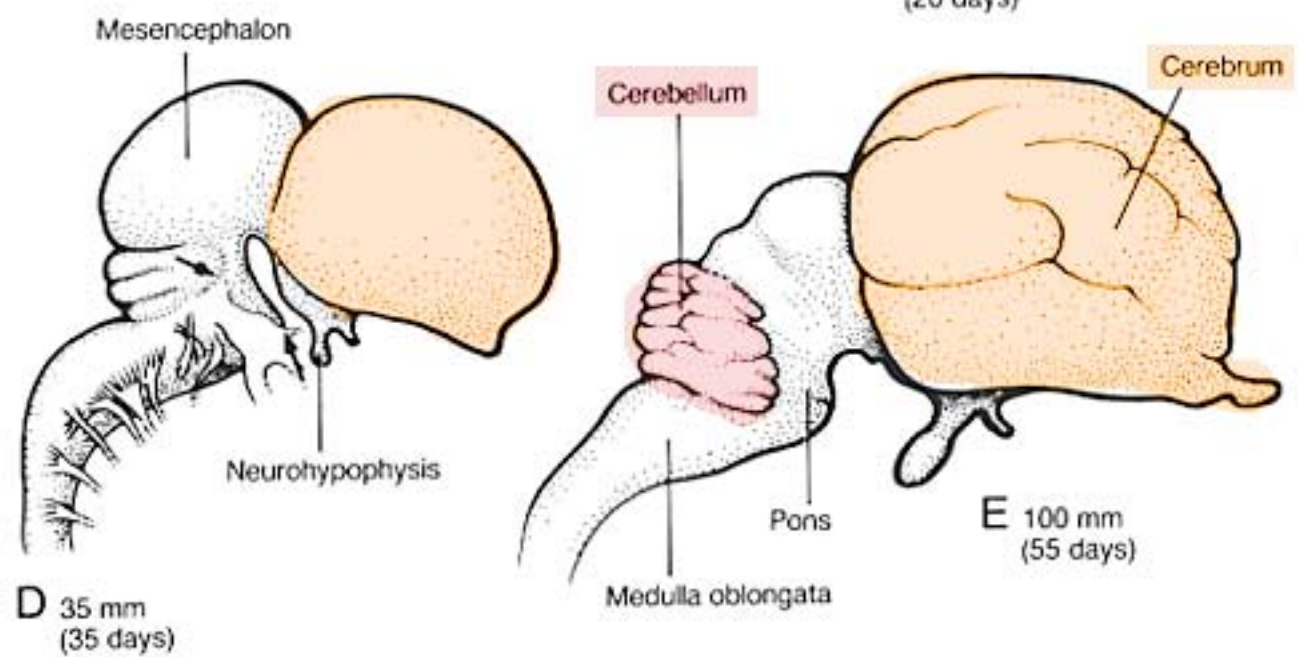
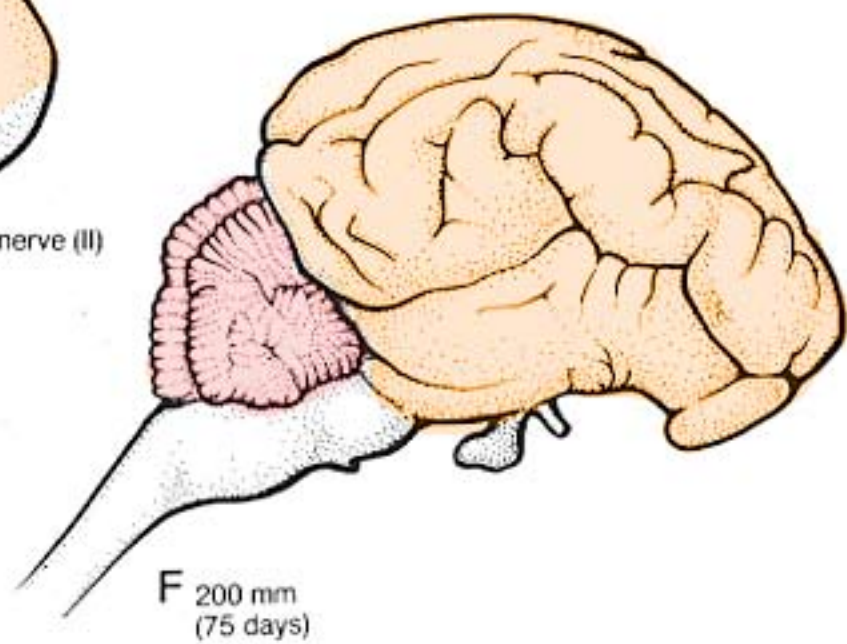
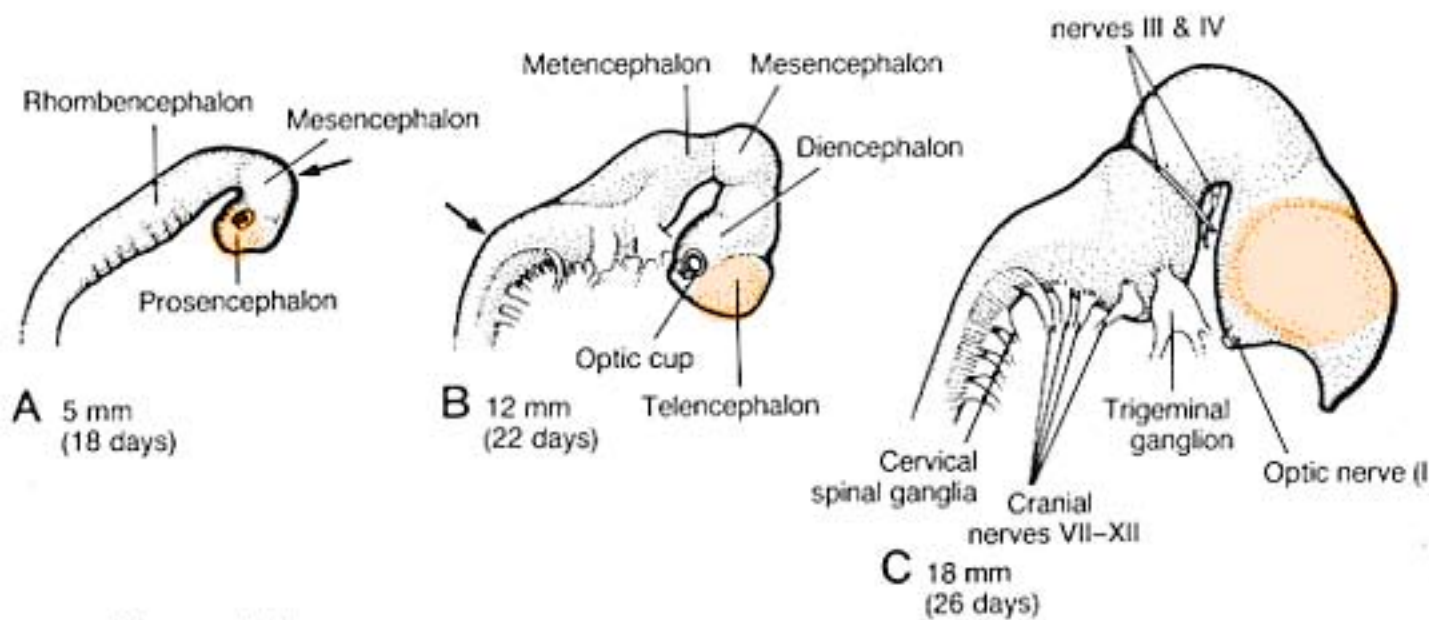
Embryonic Brain Division	Derived Brain Structures	Definitive Brain Cavities	Associated Cranial Nerves
<i>FOREBRAIN</i> Telencephalon	Cerebrum	Lateral ventricles	Olfactory (I)
Diencephalon	Thalamus; hypothalamus; etc.	Third Ventricle	Optic (II)
<i>MIDBRAIN</i> Mesencephalon	Midbrain	Mesencephalic aqueduct	III & IV
<i>HINDBRAIN</i> Metencephalon	Pons and Cerebellum	Fourth ventricle	V
Myelencephalon	Medulla Oblongata		VI—XII

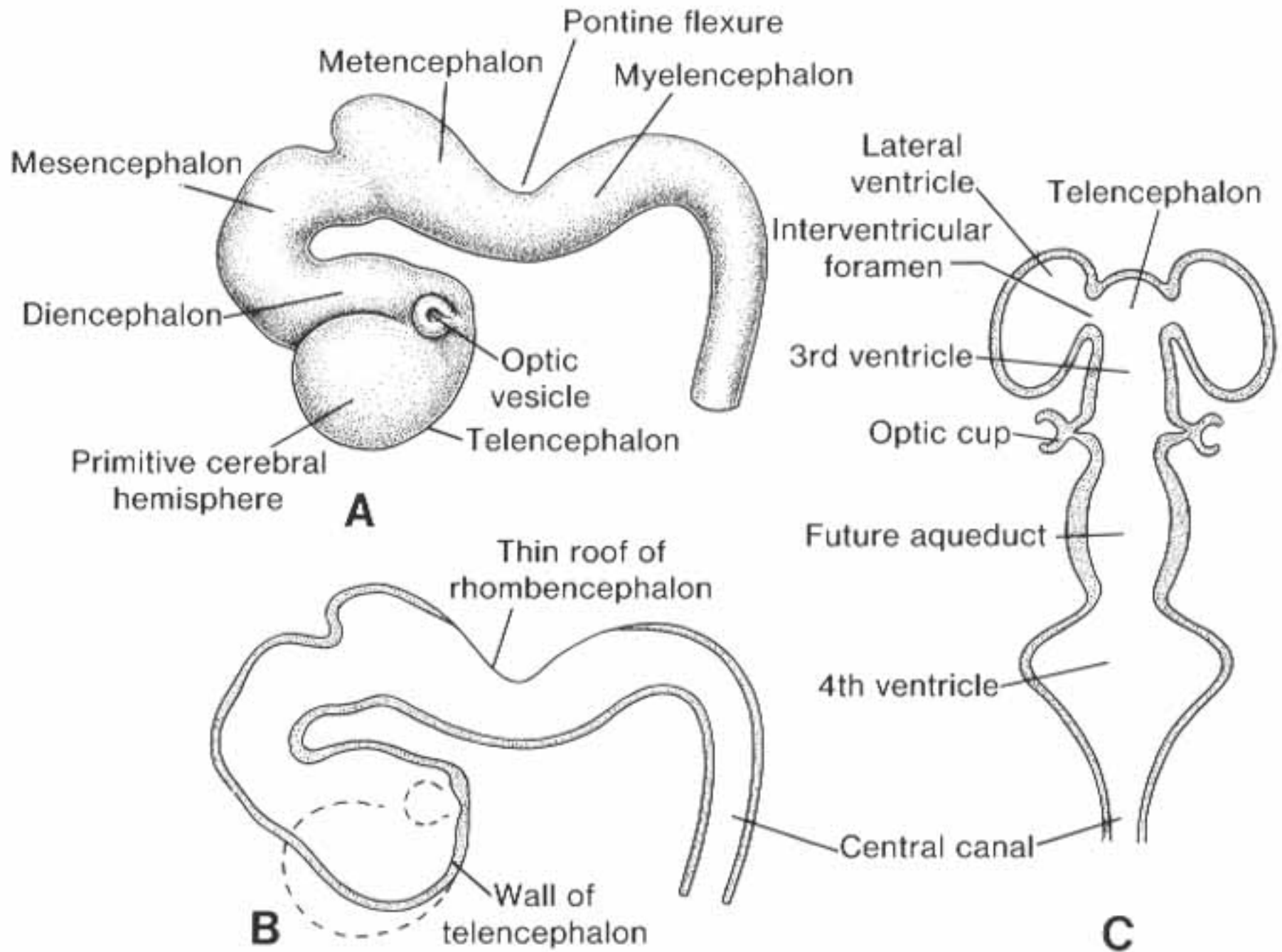
**Note:** The portion of brain remaining after the cerebrum and cerebellum are removed is referred to as the *brain stem*.



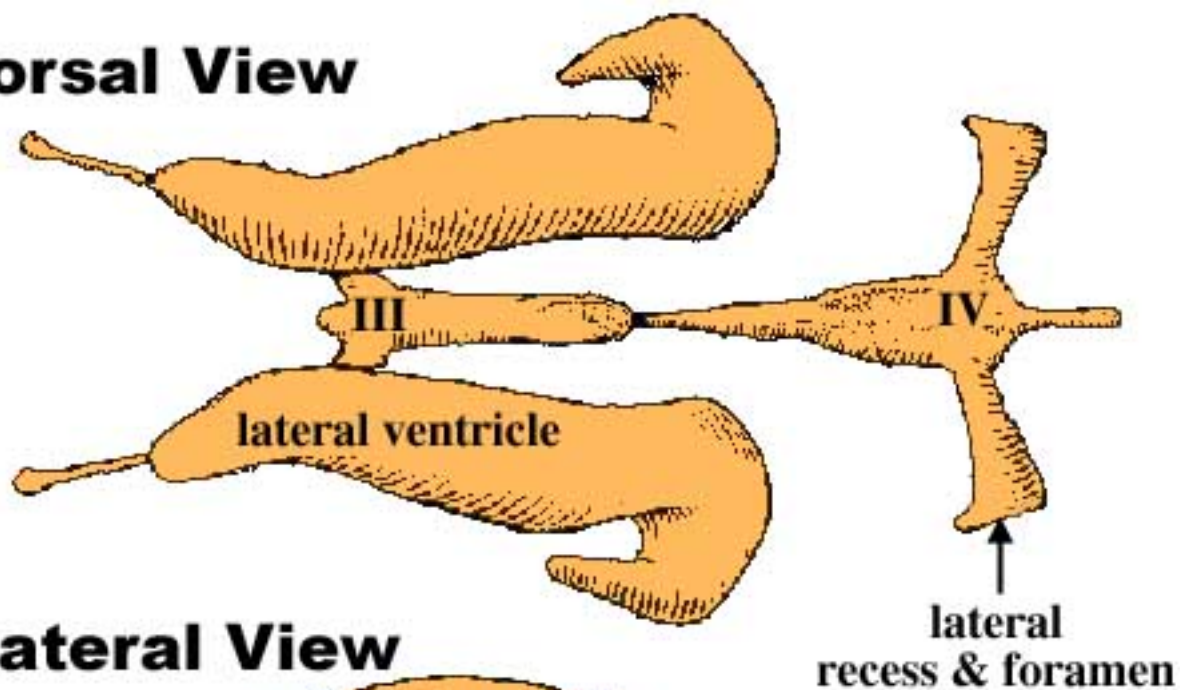


# Development of Pig Brain

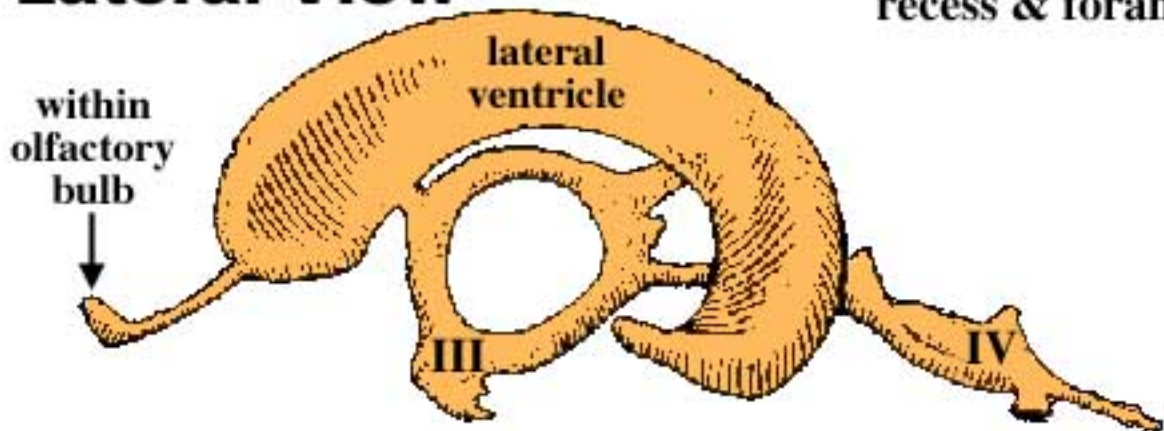




## Dorsal View



## Lateral View



# Brain Ventricular System

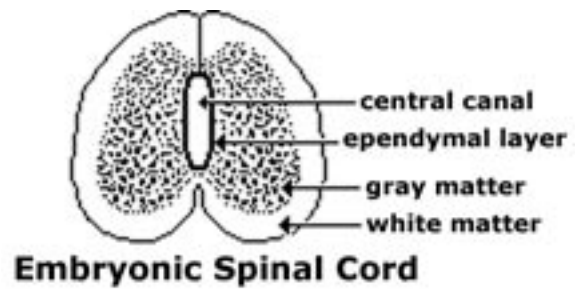
## Spinal cord development

— the neural cavity becomes *central canal* lined by ependymal cells;

— growth of alar and basal plates, but not roof and floor plates, results in symmetrical right and left halves separated by a ventral median fissure and a dorsal median fissure (or septum);

— the mantle layer develops into gray matter, i.e., dorsal and ventral *gray columns* separated by intermediate gray matter (in profile, the columns are usually called *horns*); cell migration from the basal plate produces a lateral gray column (horn) at thoracic and cranial lumbar levels of the spinal cord (sympathetic preganglionic neurons);

— the marginal layer becomes white matter (which is subdivided bilaterally into a *dorsal funiculus* (bundle), a *lateral funiculus*, and a *ventral funiculus* ).



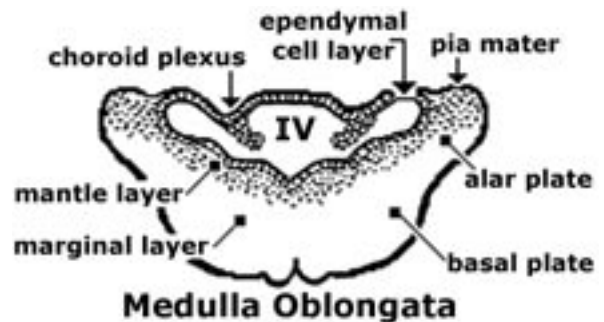
Enlargements of spinal cord segments that innervate limbs (cervical and lumbosacral enlargements) are the result of greater numbers of neurons in those segments, due to less neuronal degeneration compared to segments that do not innervate limbs.

## Hindbrain: Medulla oblongata and pons

— alar plates move laterally and the cavity of the neural tube expands dorsally forming a fourth ventricle; the roof of the fourth ventricle (roof plate) is stretched and reduced to a layer of ependymal cells covered by pia mater; a choroid plexus develops bilaterally in the roof of the ventricle and secretes cerebrospinal fluid;

— the basal plate (containing efferent neurons of cranial nerves) is positioned medial to the alar plate and ventral to the fourth ventricle;

— white and gray matter (marginal & mantle layers) become intermixed (unlike spinal cord); cerebellar development adds extra structures.

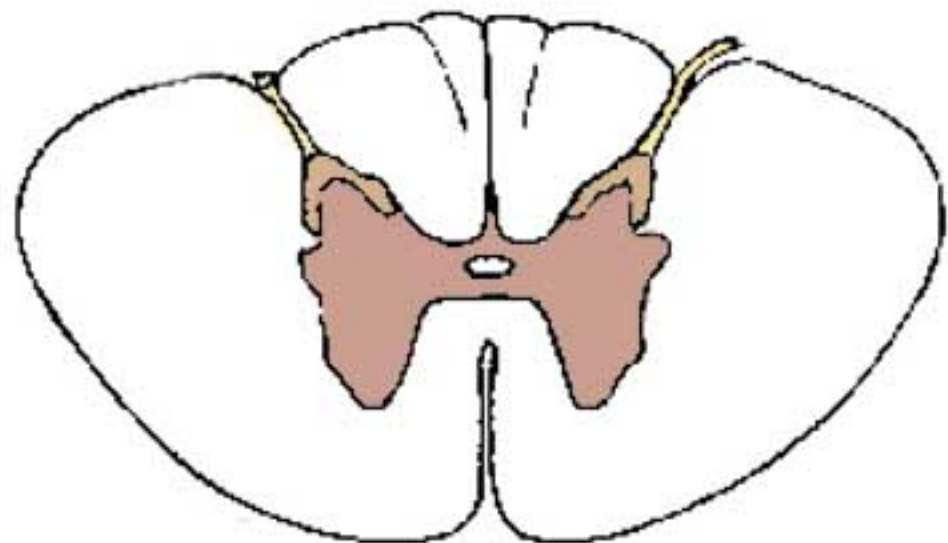


## Hindbrain: Cerebellum

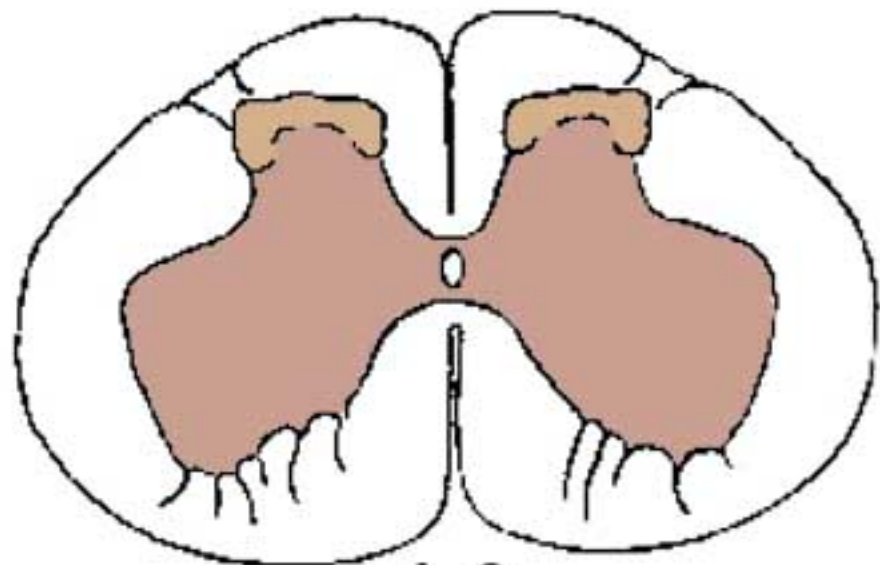
**NOTE:** • Adult cerebellum features surface gray matter, called **cerebellar cortex**, and three pair of **cerebellar nuclei** located deep within the cerebellar white matter. The cerebellum connects to the brain stem by means of three pair of *cerebellar peduncles*, each composed of white matter fibers.

- Cerebellar cortex is composed of three layers: a superficial *molecular layer* which is relatively acellular; a middle *piriform* (Purkinje) *cell layer* consisting of a row of large cell bodies; and a deep *granular* (granule cell) *layer* composed of numerous very small neurons.
- The cerebellum functions to adjust muscle tone and coordinate posture and movement so they are smooth and fluid vs. jerky and disunited.

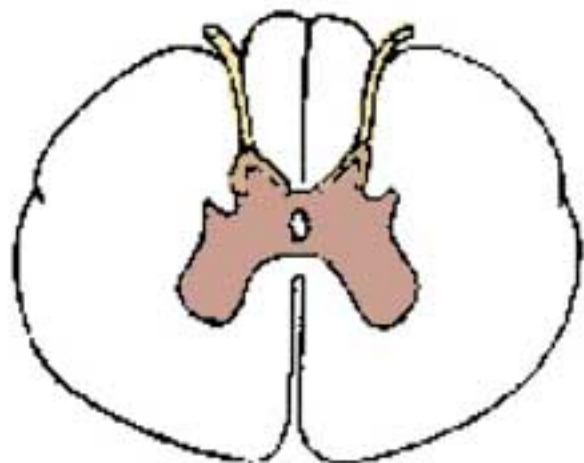
— bilateral *rhombic lips* are the first evidence of cerebellar development; the lips are expansions of the alar plate into the roof plate; the rhombic lips merge medially, forming a midline isthmus (the lips form the two cerebellar hemispheres and the isthmus forms the vermis of the cerebellum);



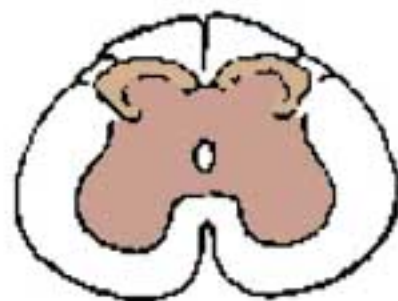
C-3



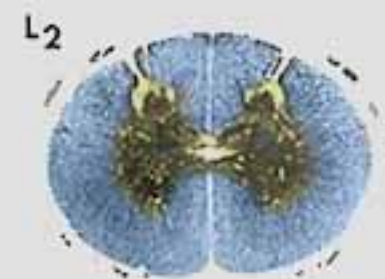
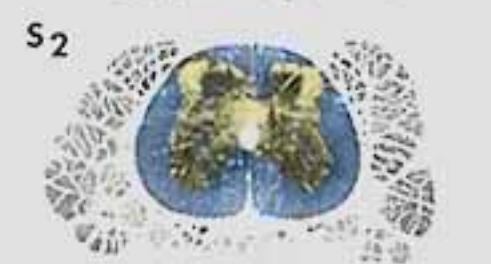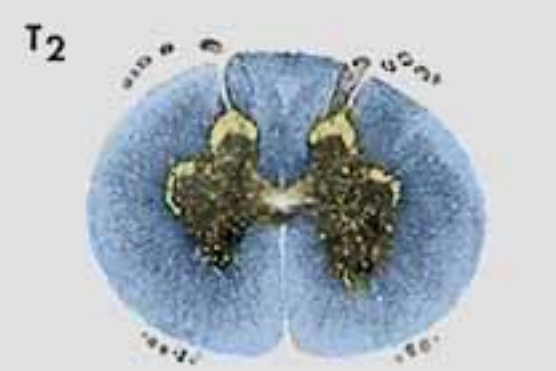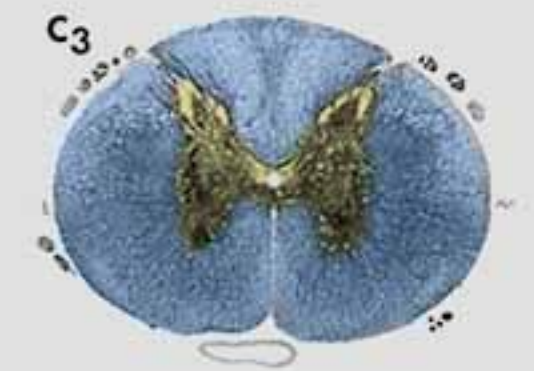
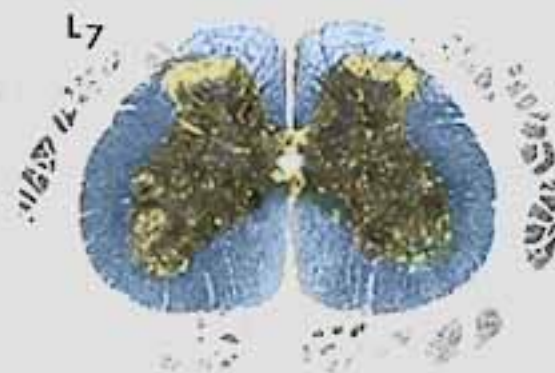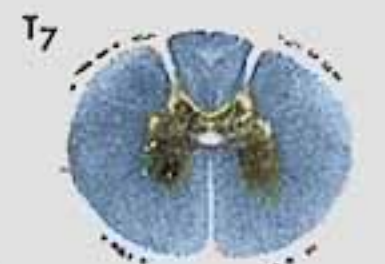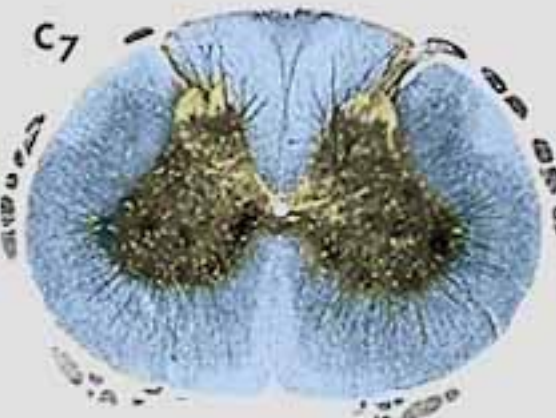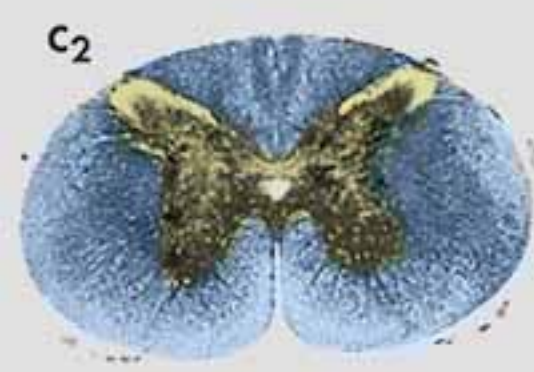
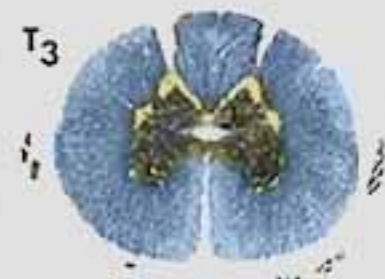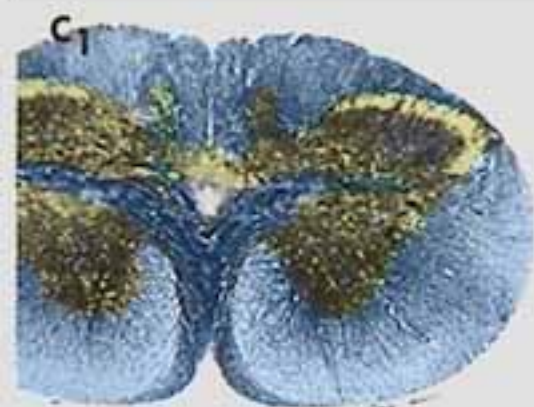L-6

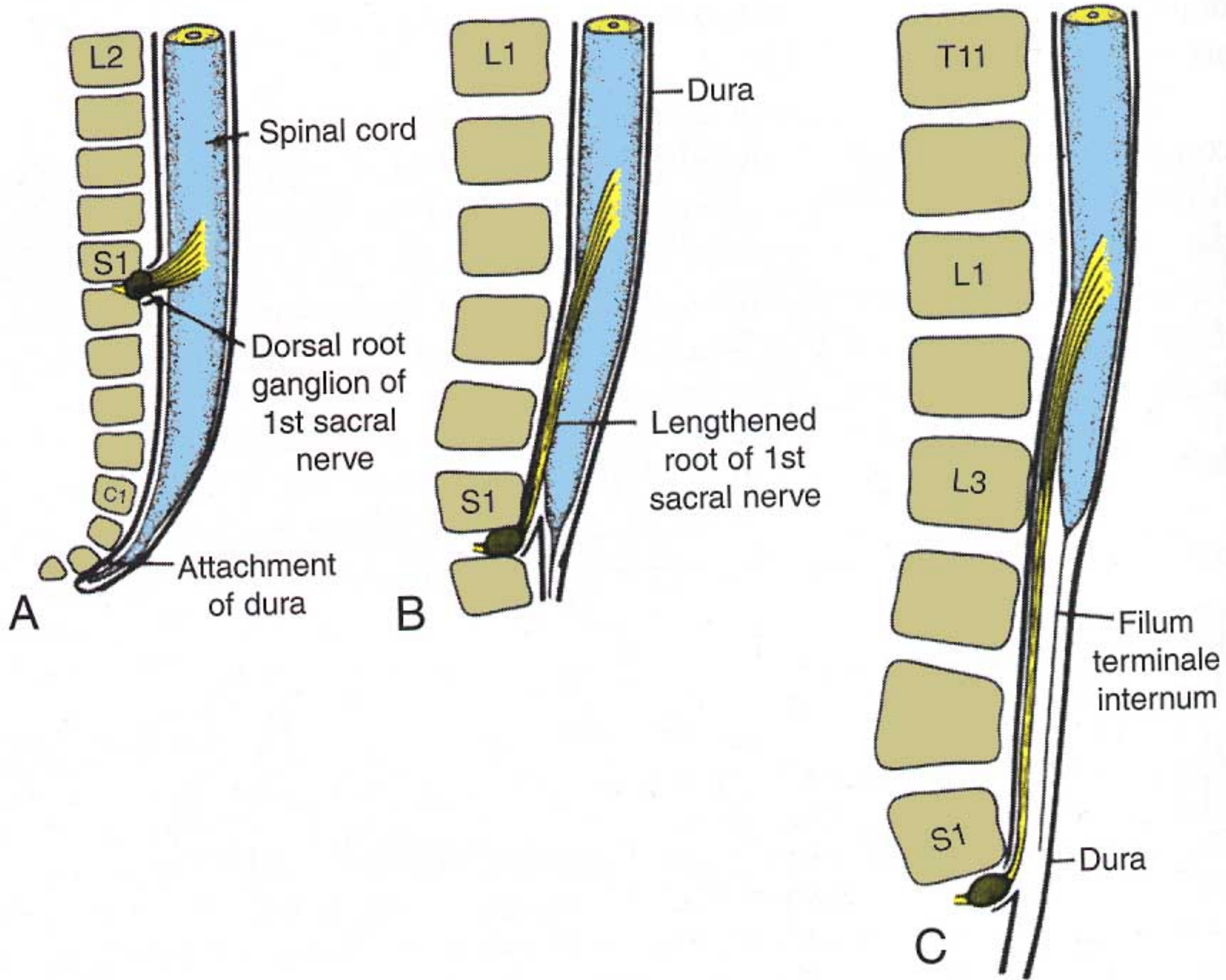


T-6

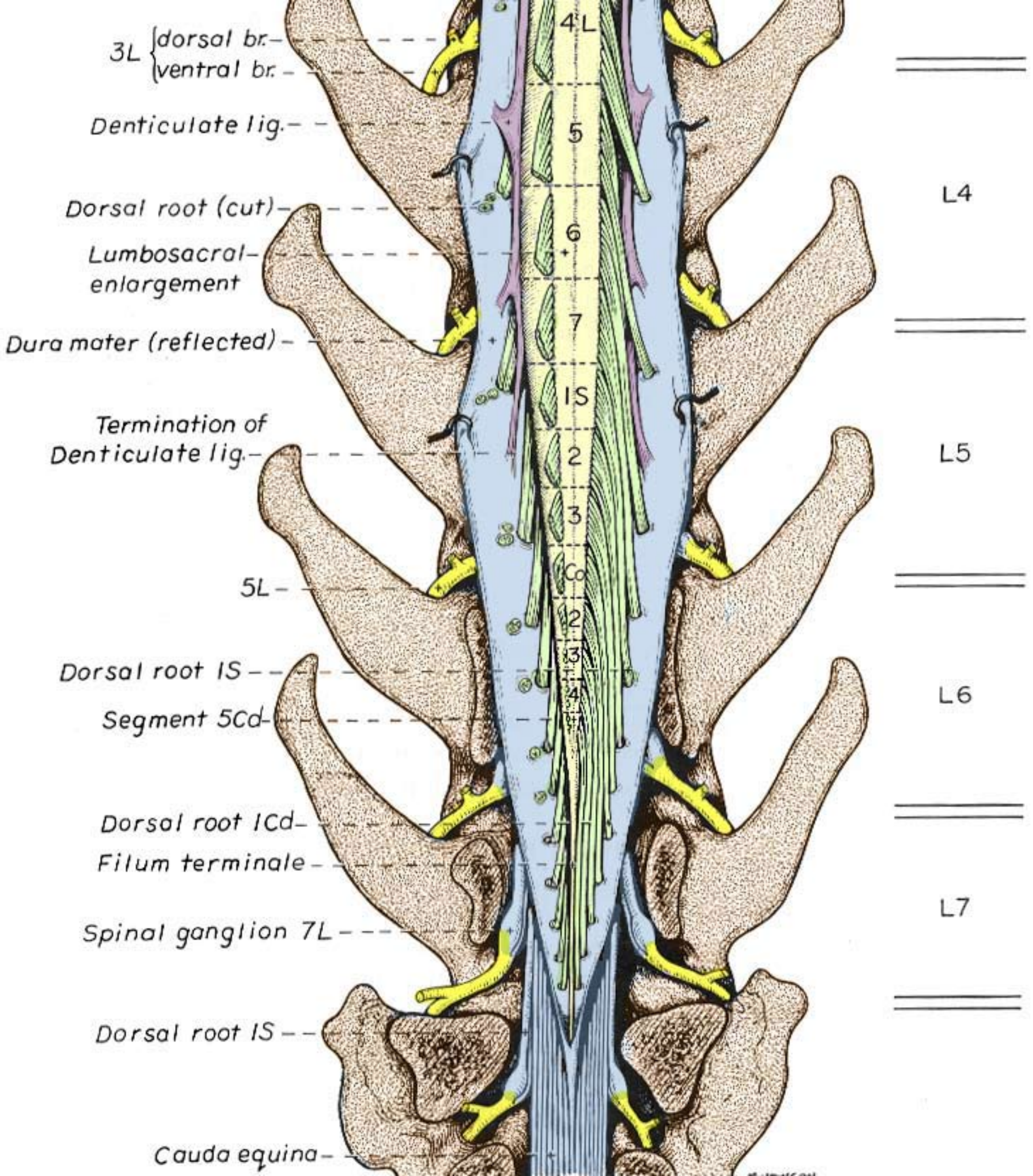


S-2









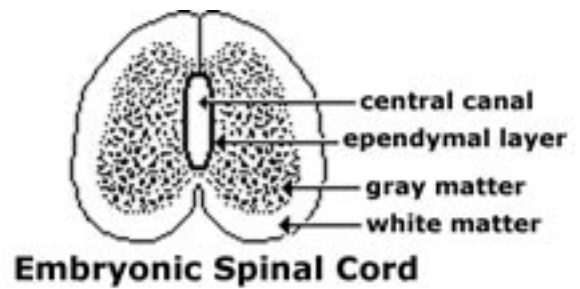
## Spinal cord development

— the neural cavity becomes *central canal* lined by ependymal cells;

— growth of alar and basal plates, but not roof and floor plates, results in symmetrical right and left halves separated by a ventral median fissure and a dorsal median fissure (or septum);

— the mantle layer develops into gray matter, i.e., dorsal and ventral *gray columns* separated by intermediate gray matter (in profile, the columns are usually called *horns*); cell migration from the basal plate produces a lateral gray column (horn) at thoracic and cranial lumbar levels of the spinal cord (sympathetic preganglionic neurons);

— the marginal layer becomes white matter (which is subdivided bilaterally into a *dorsal funiculus* (bundle), a *lateral funiculus*, and a *ventral funiculus* ).



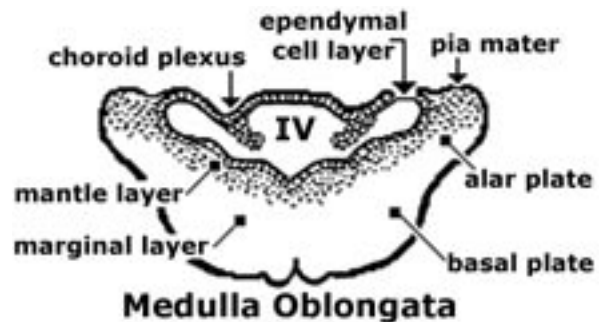
Enlargements of spinal cord segments that innervate limbs (cervical and lumbosacral enlargements) are the result of greater numbers of neurons in those segments, due to less neuronal degeneration compared to segments that do not innervate limbs.

## Hindbrain: Medulla oblongata and pons

— alar plates move laterally and the cavity of the neural tube expands dorsally forming a fourth ventricle; the roof of the fourth ventricle (roof plate) is stretched and reduced to a layer of ependymal cells covered by pia mater; a choroid plexus develops bilaterally in the roof of the ventricle and secretes cerebrospinal fluid;

— the basal plate (containing efferent neurons of cranial nerves) is positioned medial to the alar plate and ventral to the fourth ventricle;

— white and gray matter (marginal & mantle layers) become intermixed (unlike spinal cord); cerebellar development adds extra structures.

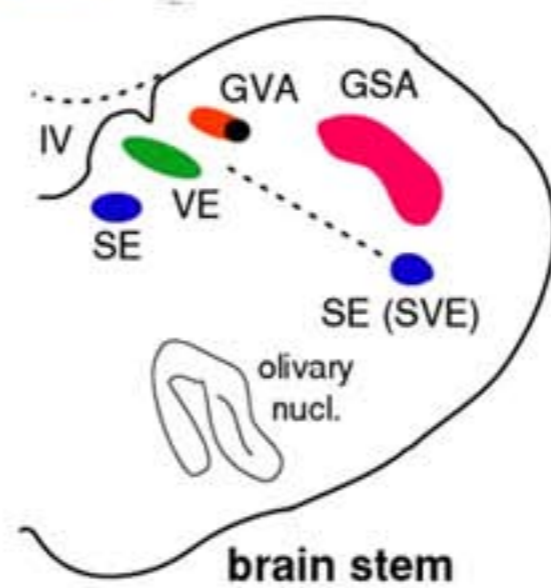
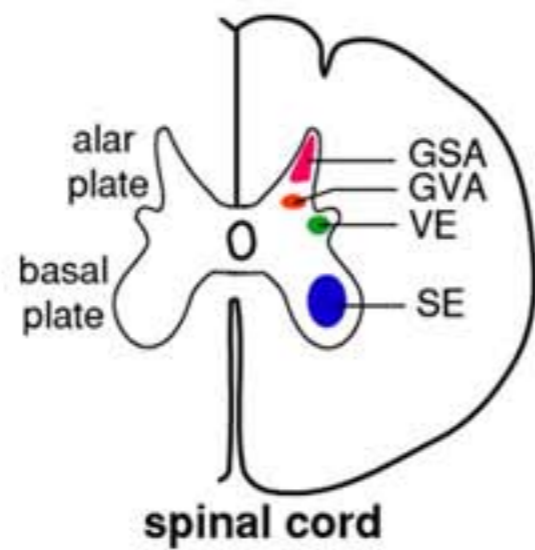
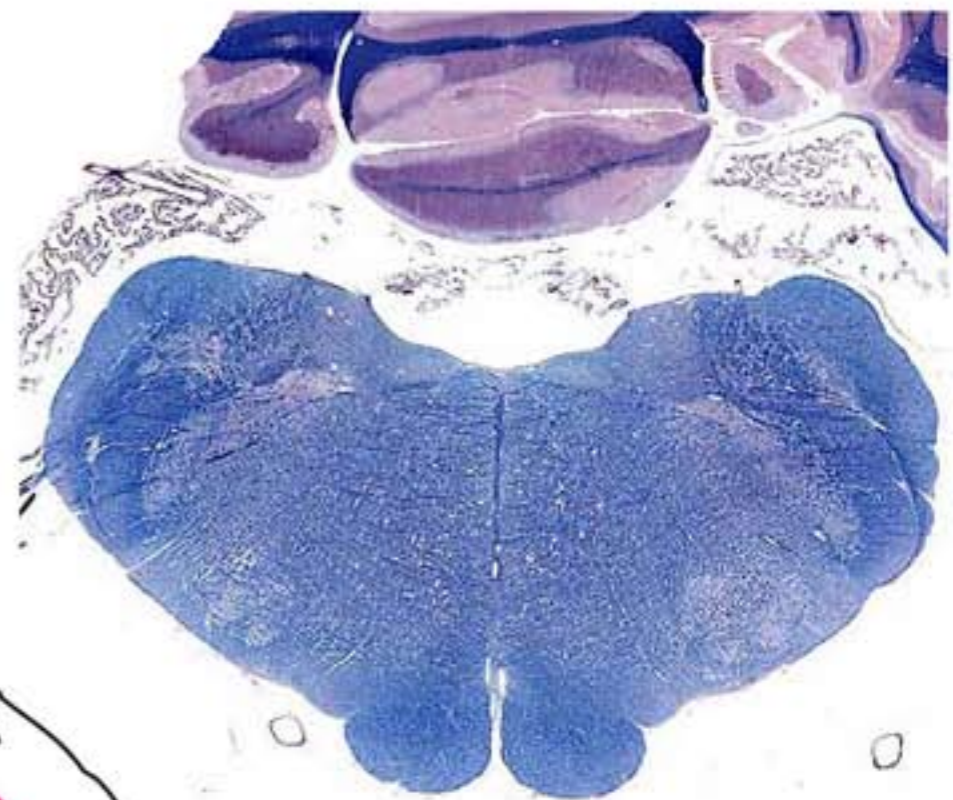
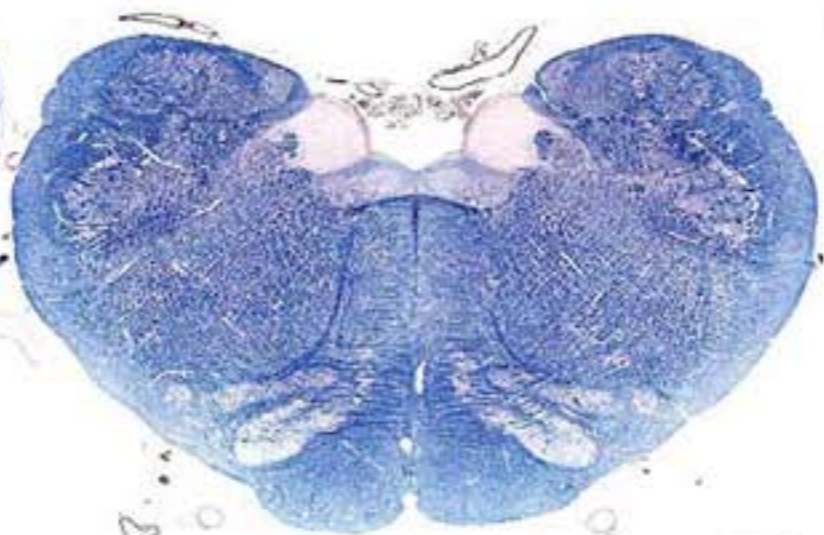
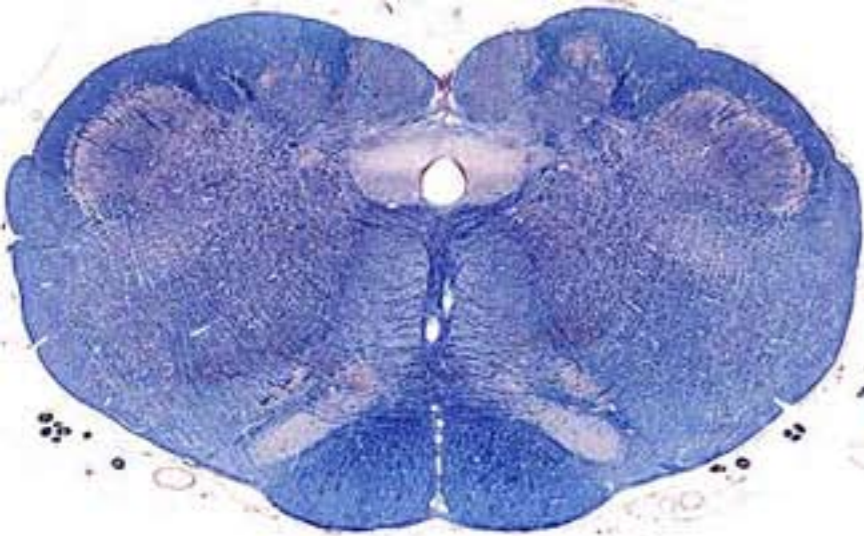


## Hindbrain: Cerebellum

*NOTE:* • Adult cerebellum features surface gray matter, called **cerebellar cortex**, and three pair of **cerebellar nuclei** located deep within the cerebellar white matter. The cerebellum connects to the brain stem by means of three pair of *cerebellar peduncles*, each composed of white matter fibers.

- Cerebellar cortex is composed of three layers: a superficial *molecular layer* which is relatively acellular; a middle *piriform* (Purkinje) *cell layer* consisting of a row of large cell bodies; and a deep *granular* (granule cell) *layer* composed of numerous very small neurons.
- The cerebellum functions to adjust muscle tone and coordinate posture and movement so they are smooth and fluid vs. jerky and disunited.

— bilateral *rhombic lips* are the first evidence of cerebellar development; the lips are expansions of the alar plate into the roof plate; the rhombic lips merge medially, forming a midline isthmus (the lips form the two cerebellar hemispheres and the isthmus forms the vermis of the cerebellum);



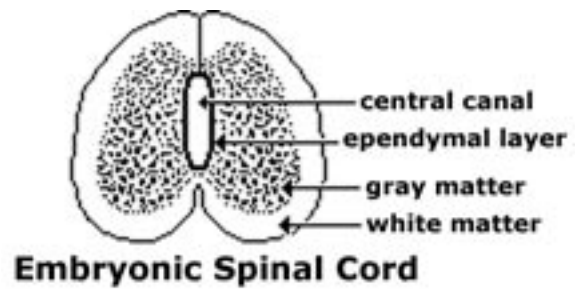
## Spinal cord development

— the neural cavity becomes *central canal* lined by ependymal cells;

— growth of alar and basal plates, but not roof and floor plates, results in symmetrical right and left halves separated by a ventral median fissure and a dorsal median fissure (or septum);

— the mantle layer develops into gray matter, i.e., dorsal and ventral *gray columns* separated by intermediate gray matter (in profile, the columns are usually called *horns*); cell migration from the basal plate produces a lateral gray column (horn) at thoracic and cranial lumbar levels of the spinal cord (sympathetic preganglionic neurons);

— the marginal layer becomes white matter (which is subdivided bilaterally into a *dorsal funiculus* (bundle), a *lateral funiculus*, and a *ventral funiculus* ).



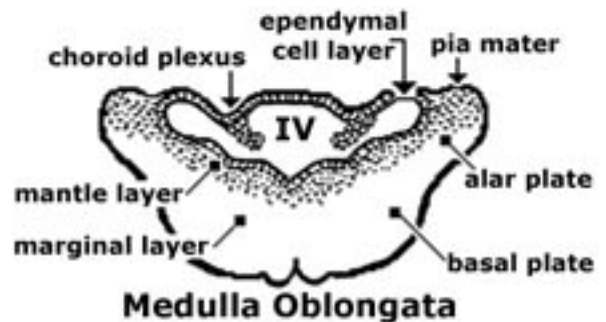
Enlargements of spinal cord segments that innervate limbs (cervical and lumbosacral enlargements) are the result of greater numbers of neurons in those segments, due to less neuronal degeneration compared to segments that do not innervate limbs.

## Hindbrain: Medulla oblongata and pons

— alar plates move laterally and the cavity of the neural tube expands dorsally forming a fourth ventricle; the roof of the fourth ventricle (roof plate) is stretched and reduced to a layer of ependymal cells covered by pia mater; a choroid plexus develops bilaterally in the roof of the ventricle and secretes cerebrospinal fluid;

— the basal plate (containing efferent neurons of cranial nerves) is positioned medial to the alar plate and ventral to the fourth ventricle;

— white and gray matter (marginal & mantle layers) become intermixed (unlike spinal cord); cerebellar development adds extra structures.



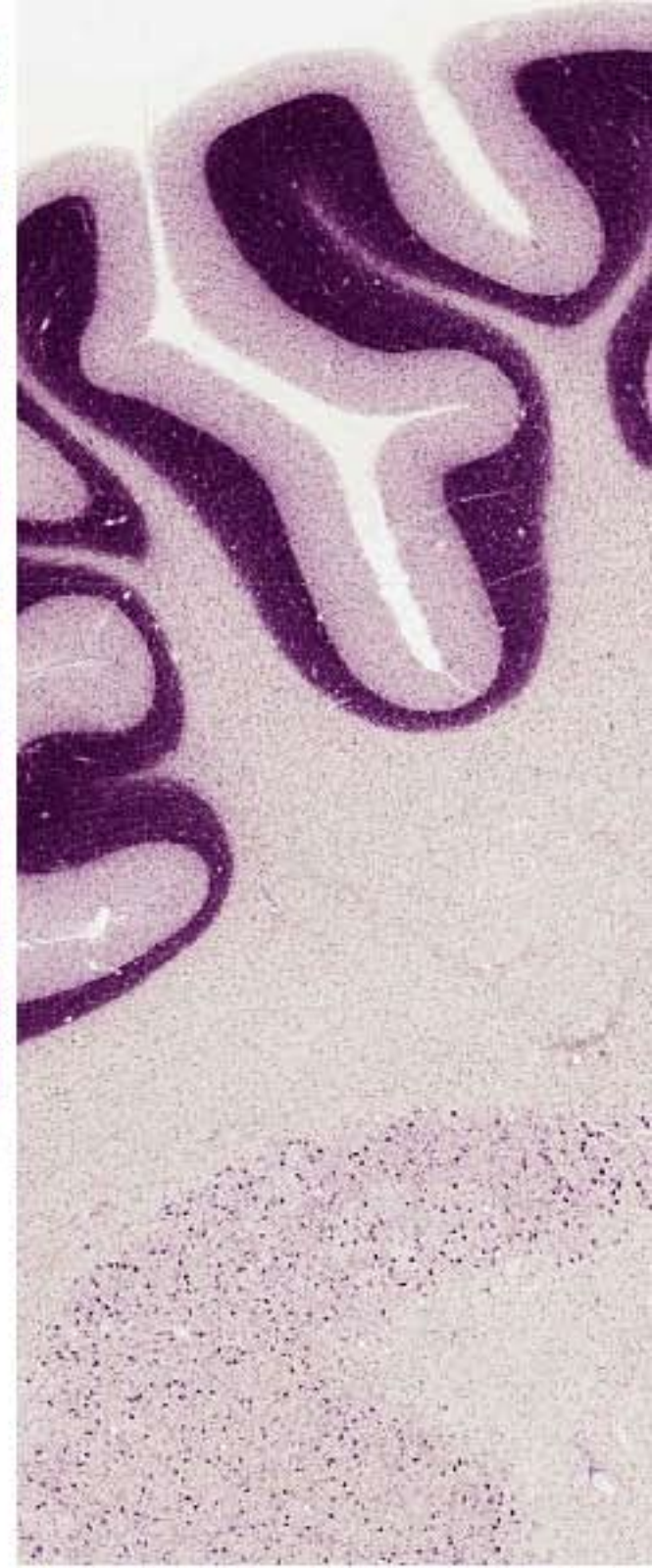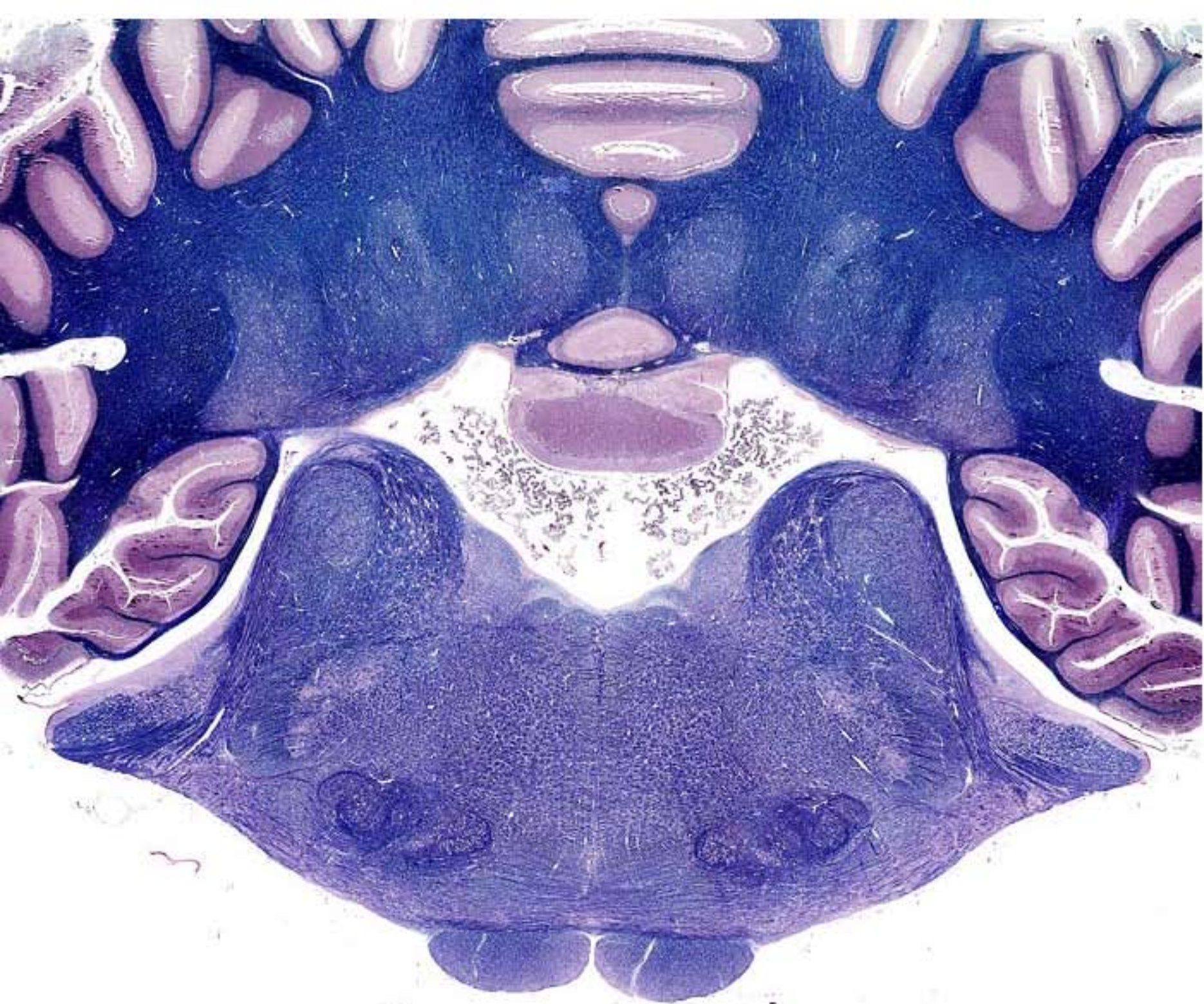
## Hindbrain: Cerebellum

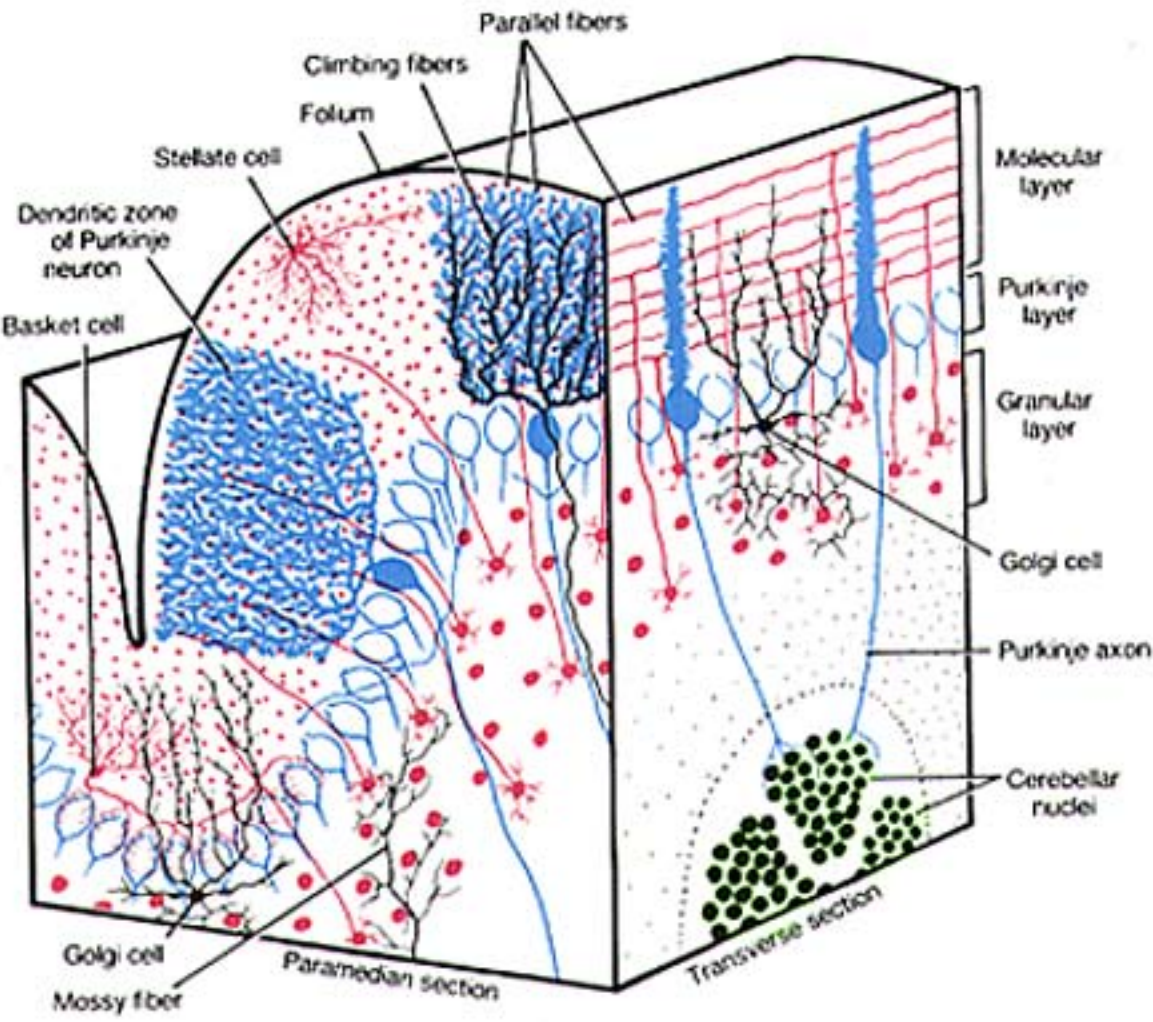
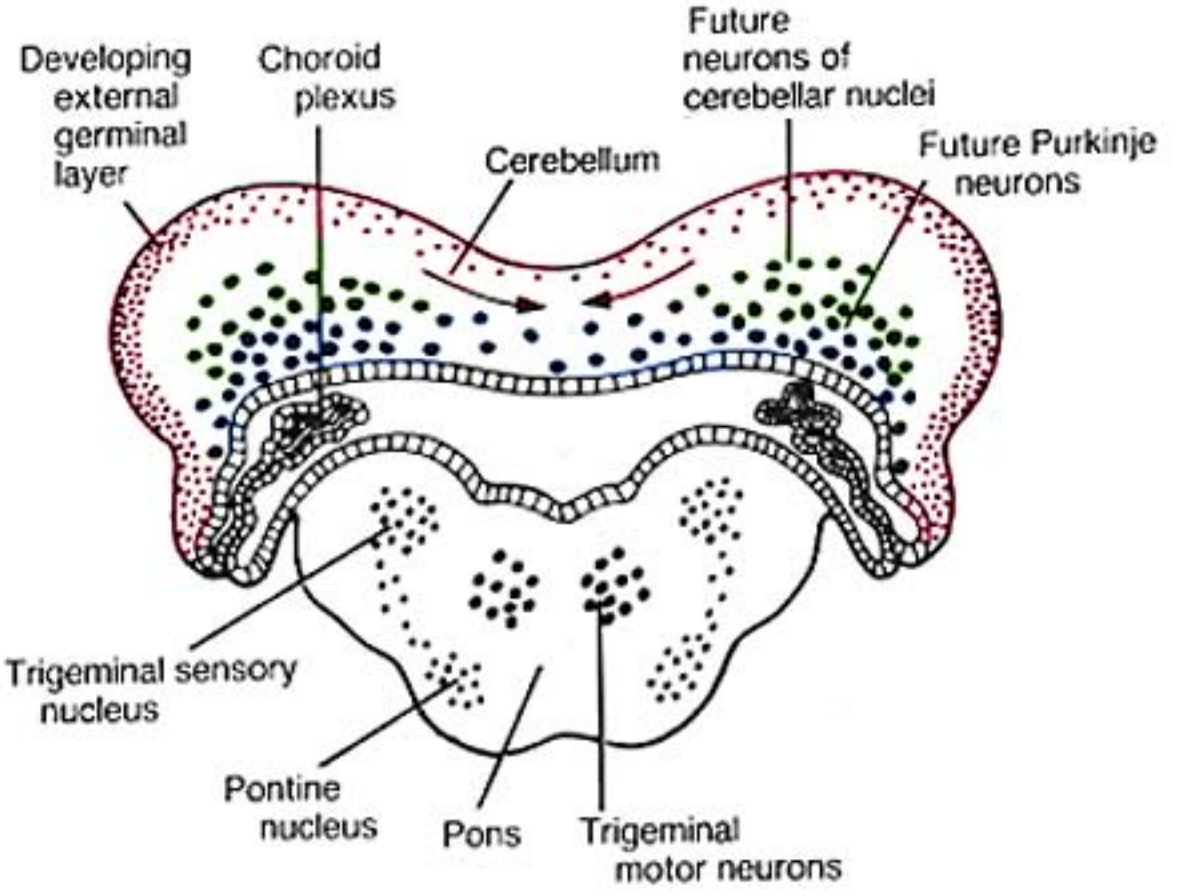
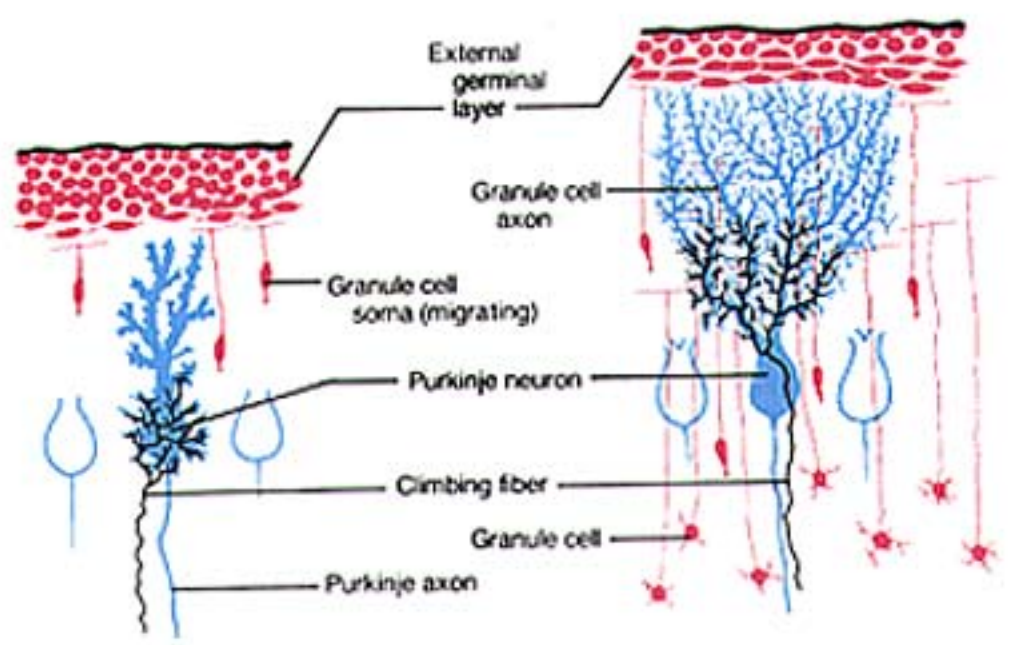
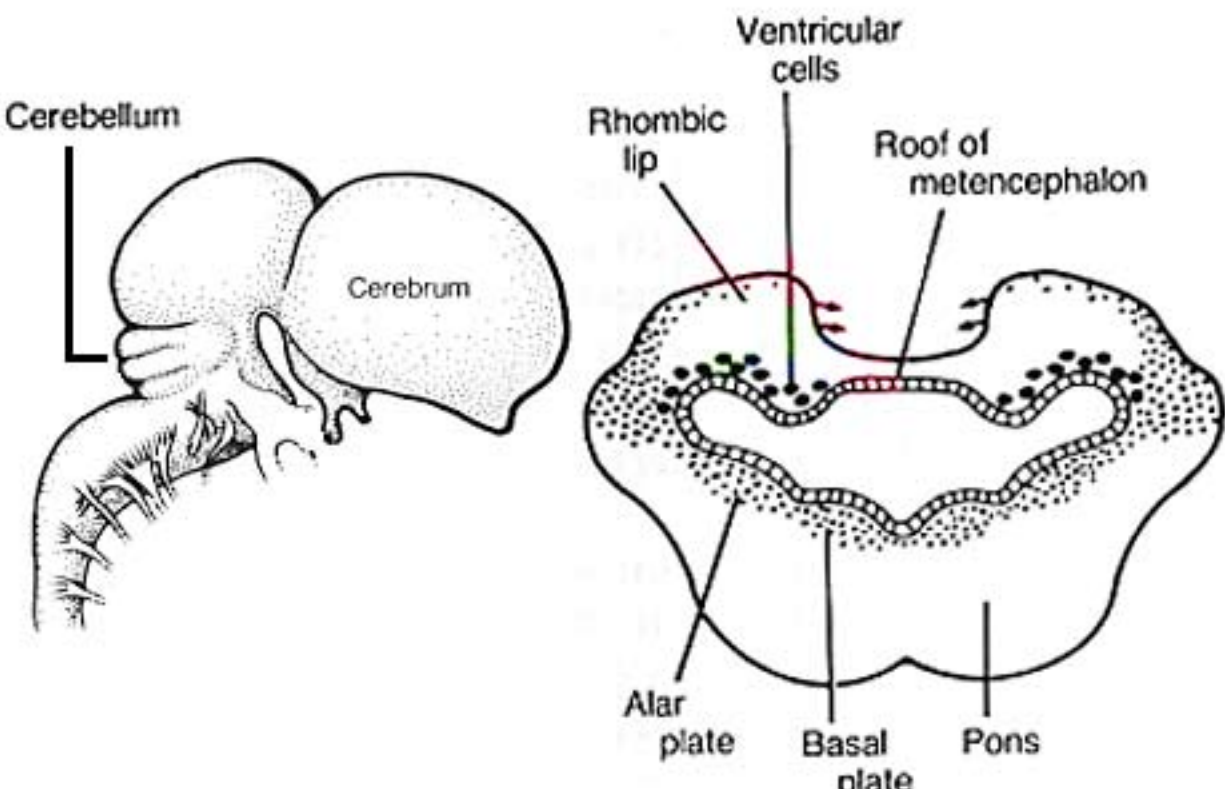
**NOTE:** • Adult cerebellum features surface gray matter, called **cerebellar cortex**, and three pair of **cerebellar nuclei** located deep within the cerebellar white matter. The cerebellum connects to the brain stem by means of three pair of *cerebellar peduncles*, each composed of white matter fibers.

• Cerebellar cortex is composed of three layers: a superficial *molecular layer* which is relatively acellular; a middle *piriform* (Purkinje) *cell layer* consisting of a row of large cell bodies; and a deep *granular* (granule cell) *layer* composed of numerous very small neurons.

• The cerebellum functions to adjust muscle tone and coordinate posture and movement so they are smooth and fluid vs. jerky and disunited.

— bilateral *rhombic lips* are the first evidence of cerebellar development; the lips are expansions of the alar plate into the roof plate; the rhombic lips merge medially, forming a midline isthmus (the lips form the two cerebellar hemispheres and the isthmus forms the vermis of the cerebellum);

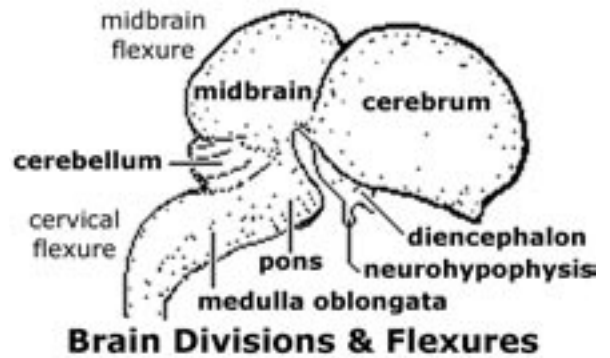




– cellular migrations:

- superficial and deep layers of neurons are evident within the mantle layer of the future cerebellum; the deep cells migrate (pass the superficial cells) toward the cerebellar surface and become Purkinje cells of the cerebellar cortex; meanwhile, neurons of the superficial layer migrate deeply and become cerebellar nuclei;

- neuroblasts located laterally in the rhombic lip migrate along the outer surface of the cerebellum, forming an *external germinal layer* (which continues to undergo mitosis); subsequently, neurons migrate deep to the Purkinje cells and form the granule cell layer of the cerebellar cortex;
- some alar plate neurons migrate to the ventral surface of the pons, forming pontine nuclei which send axons to the cerebellum.



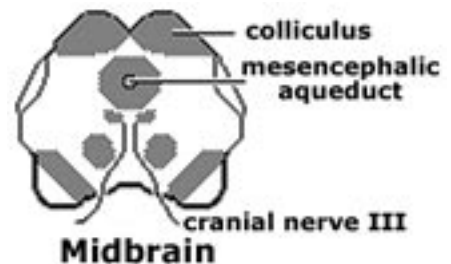
Migration of neuron populations past one another allows connections to be established between neurons of the respective populations. Neurons that fail to connect are destined to degenerate. Connections are made by axons that subsequently elongate as neurons migrate during growth.

## Midbrain

– the neural cavity of the midbrain becomes *mesencephalic aqueduct* (which is not a ventricle because it is completely surrounded by brain tissue and thus it lacks a choroid plexus).

– alar plates form two pairs of dorsal bulges which become rostral and caudal colliculi (associated with visual and auditory reflexes, respectively);

– the basal plate gives rise to oculomotor (III) and trochlear (IV) nerves which innervate muscles that move the eyes.



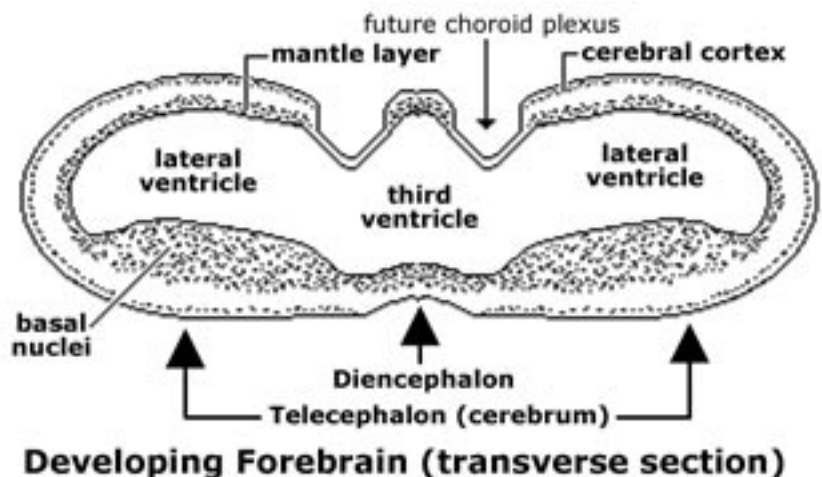
*Note:* The midbrain is the rostral extent of the basal plate (efferent neurons).

## Forebrain (derived entirely from alar plate)

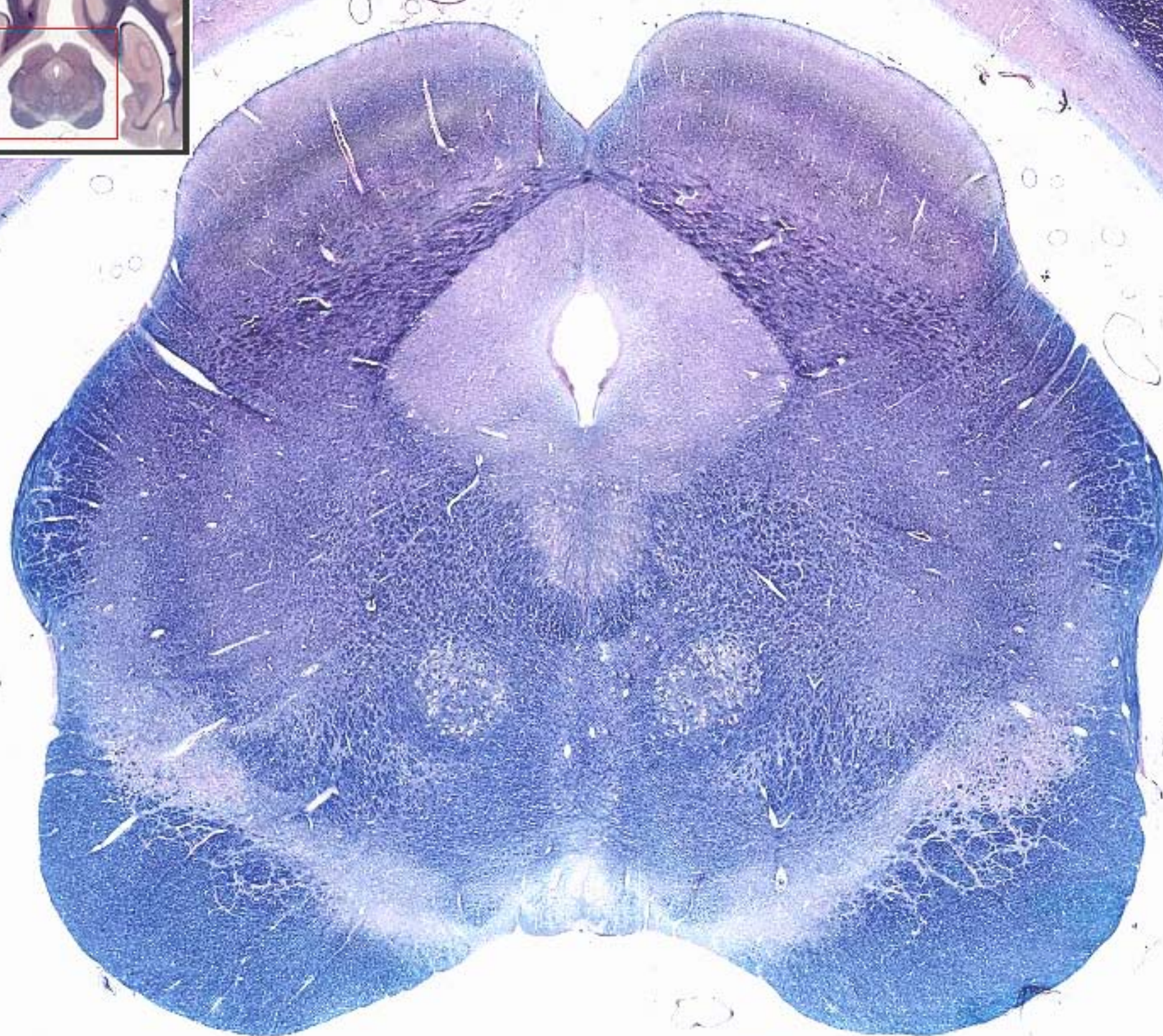
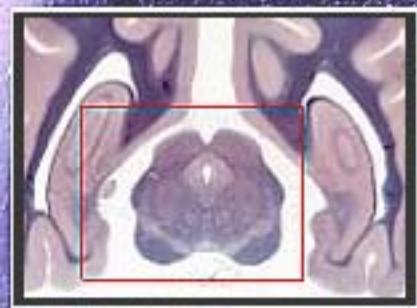### Diencephalon:

– the neural cavity expands dorsoventrally and becomes the narrow *third ventricle*, the roof plate is stretched and choroid plexuses develop bilaterally in the roof of the third ventricle and secrete cerebrospinal fluid;

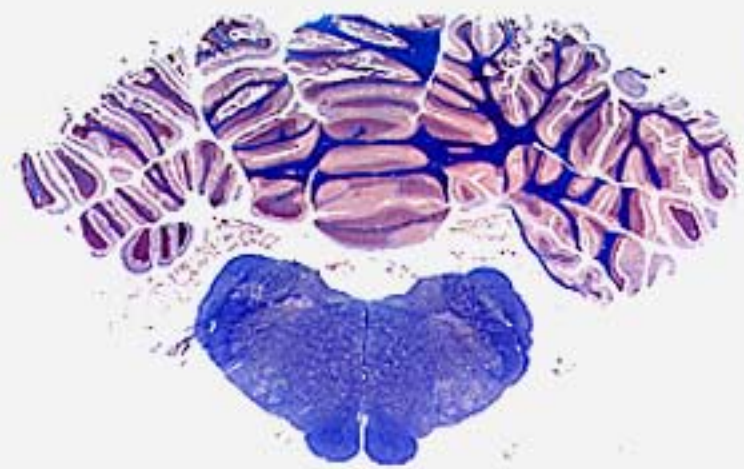
– the floor of the third ventricle gives rise to the neurohypophysis (neural lobe of the pituitary gland);



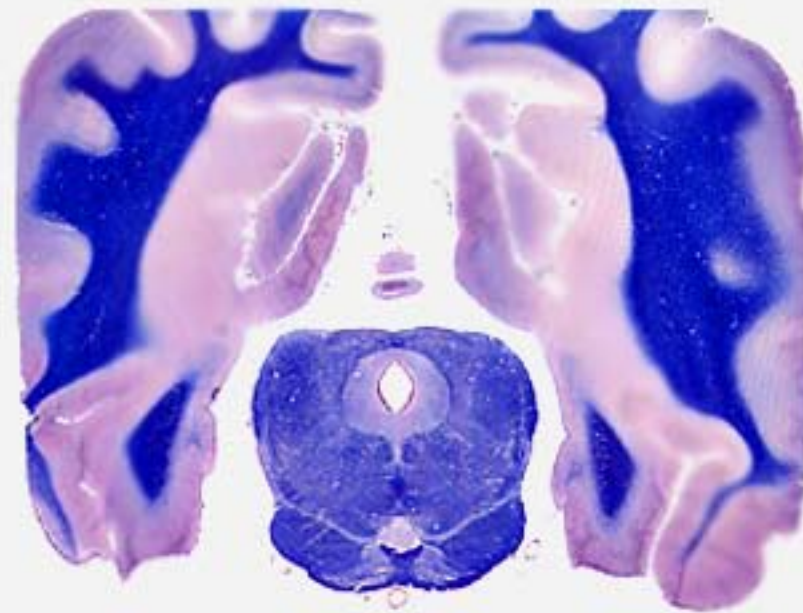
Canine



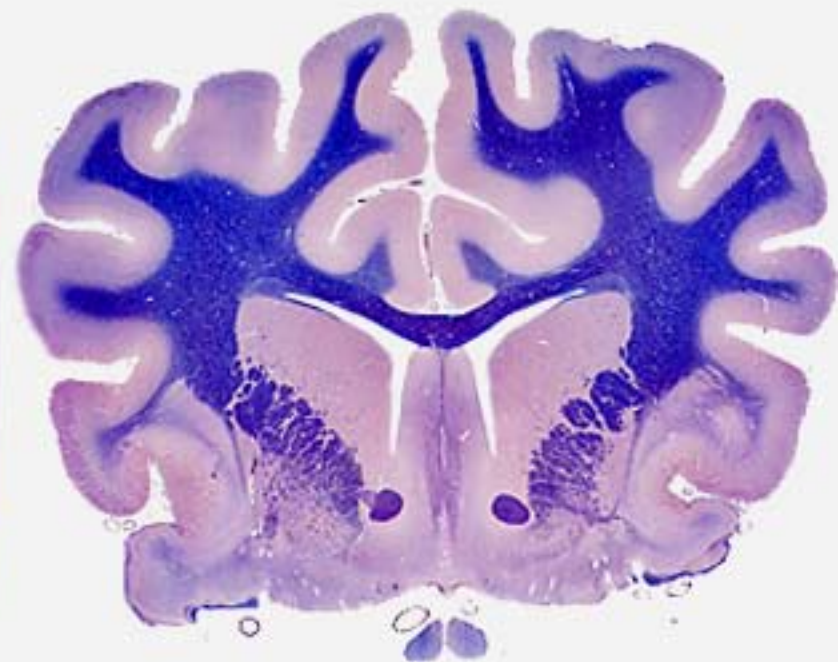




**Hindbrain**

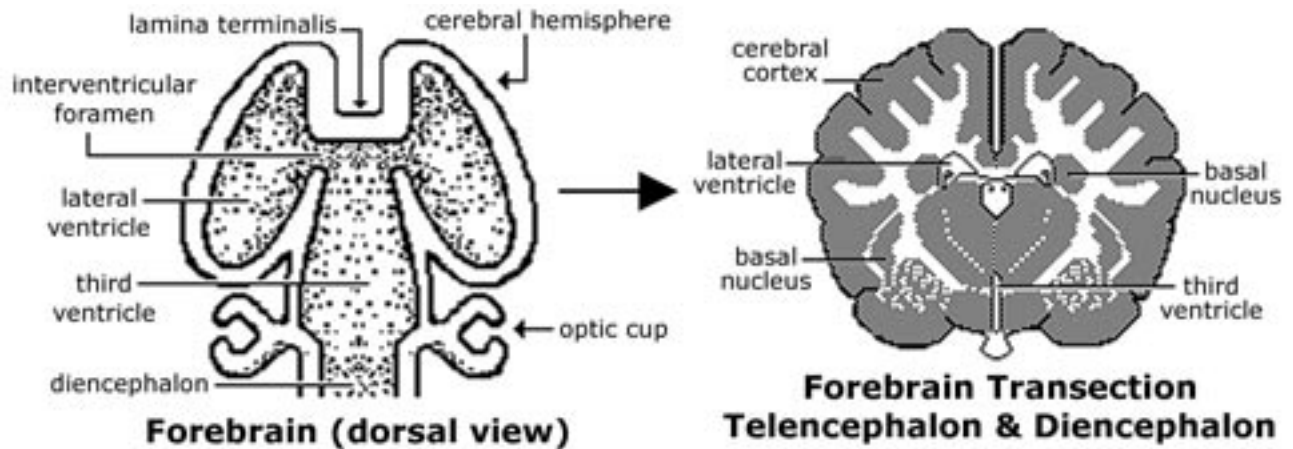


**Midbrain**



**Forebrain**

- the mantle layer of the diencephalon gives rise to thalamus, hypothalamus, etc.; the thalamus enlarges to the point where right and left sides meet at the midline and obliterate the center of the third ventricle.
- the optic nerve develops from an outgrowth of the wall of the diencephalon.

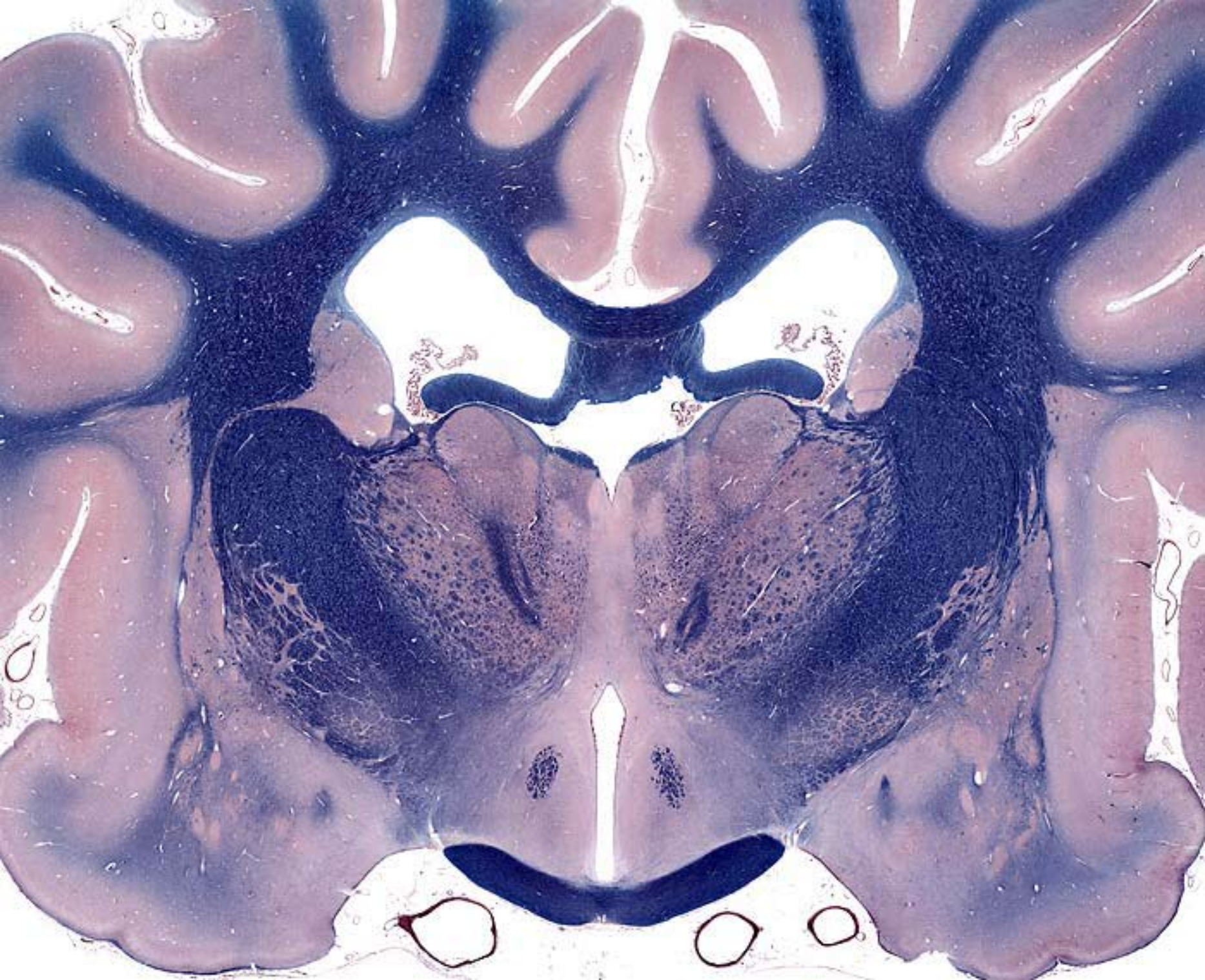


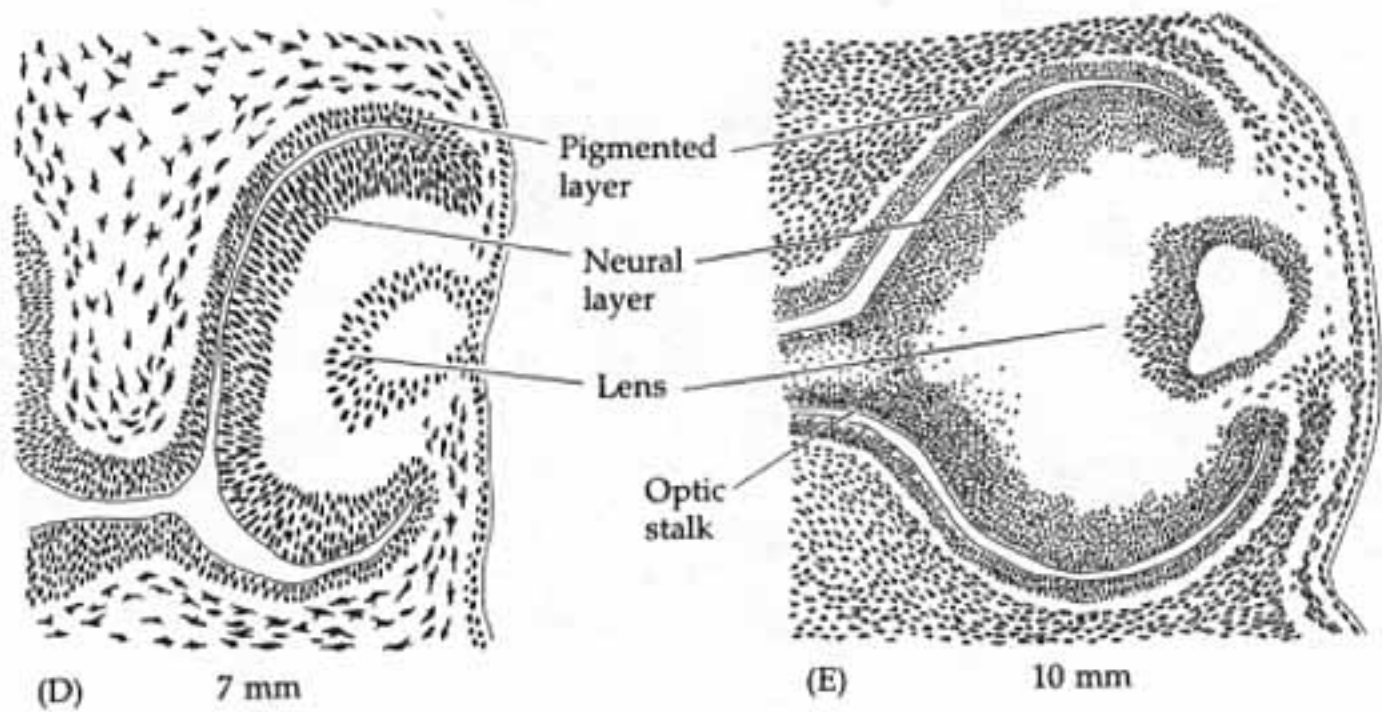
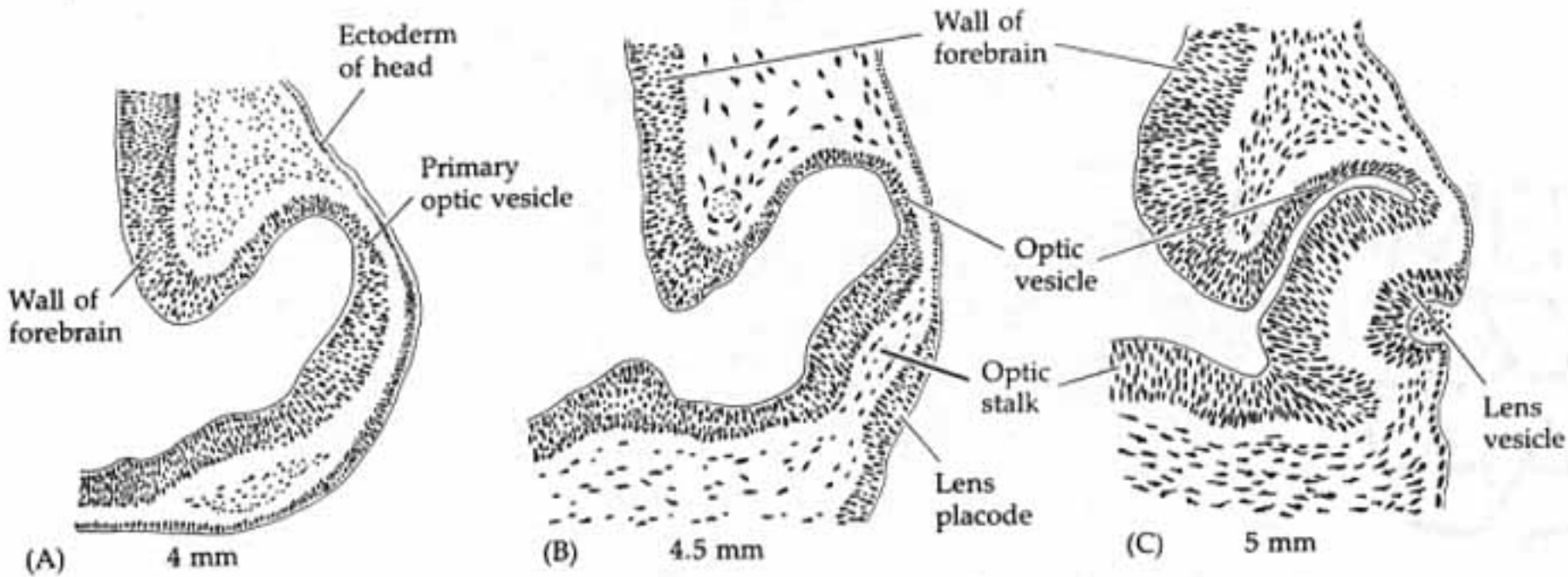
### Telencephalon (cerebrum):

- bilateral hollow outgrowths become right and left *cerebral hemispheres*; the cavity of each outgrowth forms a *lateral ventricle* that communicates with the third ventricle via an interventricular foramen (in the wall of each lateral ventricle, a choroid plexus develops that is continuous with a choroid plexus of the third ventricle via an interventricular foramen);
  - at the midline, the rostral end of the telencephalon forms the rostral wall of the third ventricle (the wall is designated lamina terminalis);
  - the mantle layer surrounding the lateral ventricle in each hemisphere gives rise to basal nuclei and *cerebral cortex*;
  - cellular migrations that form cerebral cortex:
    - from the mantle layer, cells migrate radially to the surface of the cerebral hemisphere, guided by glial cells that extend from the ventricular surface to the outer surface of the cerebral wall (thus each locus of mantle gives rise to a specific area of cerebral cortex);
    - migration occurs in waves; the first wave (which becomes the deepest layer of cortex) migrates to the surface of the cortex; the second wave (which forms the next deepest layer of cortex) migrates to the cortical surface, passing through first wave neurons which are displaced to a deeper position; the third wave . . . etc. (the cerebral cortex has six layers).

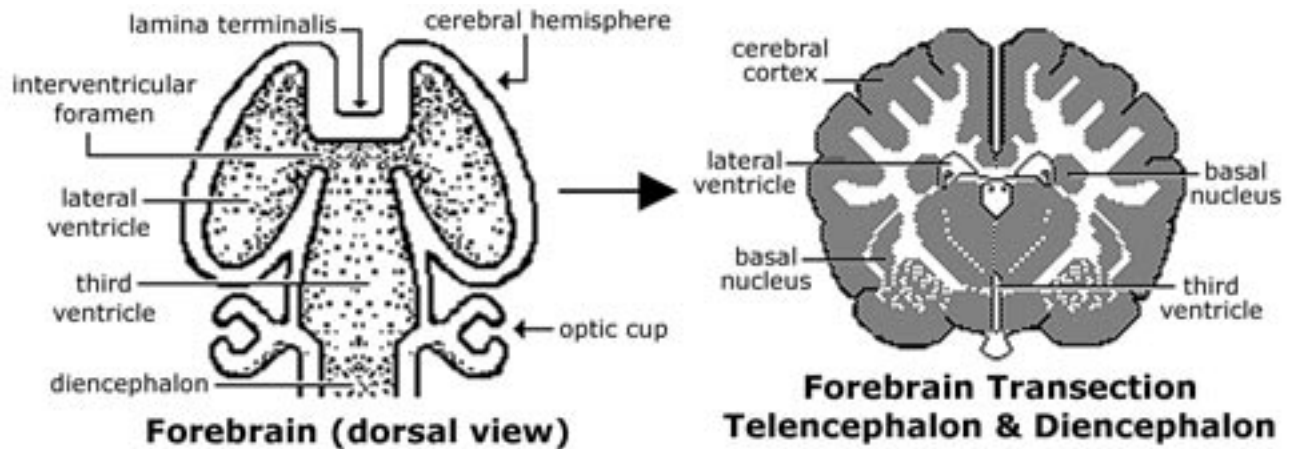
Cell connections are established within the cerebral cortex as waves of newly arriving neurons migrate through populations of neurons that arrived earlier.

NOTE: Carnivores are born with a nervous system that does not mature until about six weeks postnatally (mature behavior is correspondingly delayed). In herbivores, the nervous system is close to being mature at birth.





- the mantle layer of the diencephalon gives rise to thalamus, hypothalamus, etc.; the thalamus enlarges to the point where right and left sides meet at the midline and obliterate the center of the third ventricle.
- the optic nerve develops from an outgrowth of the wall of the diencephalon.

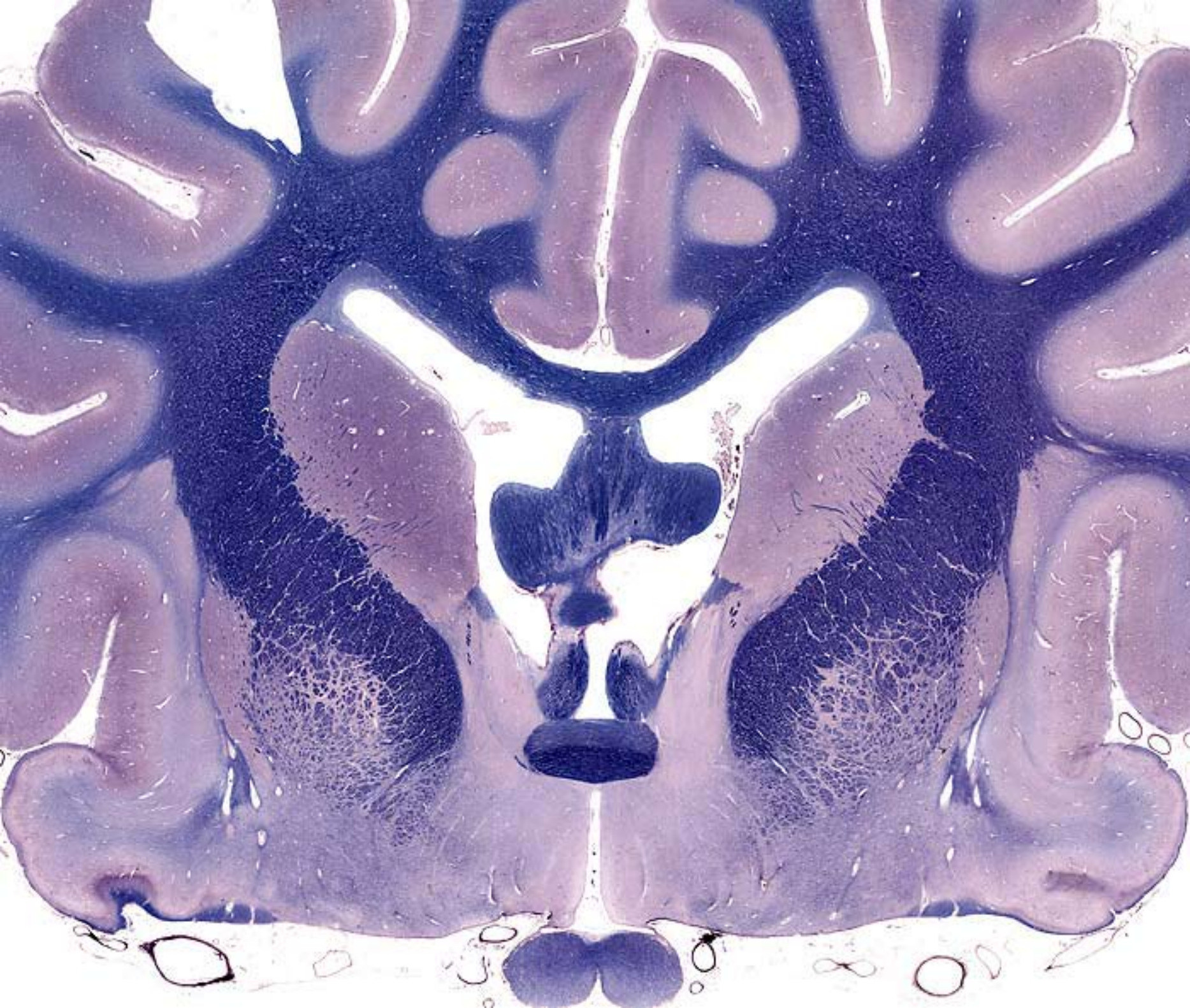


### Telencephalon (cerebrum):

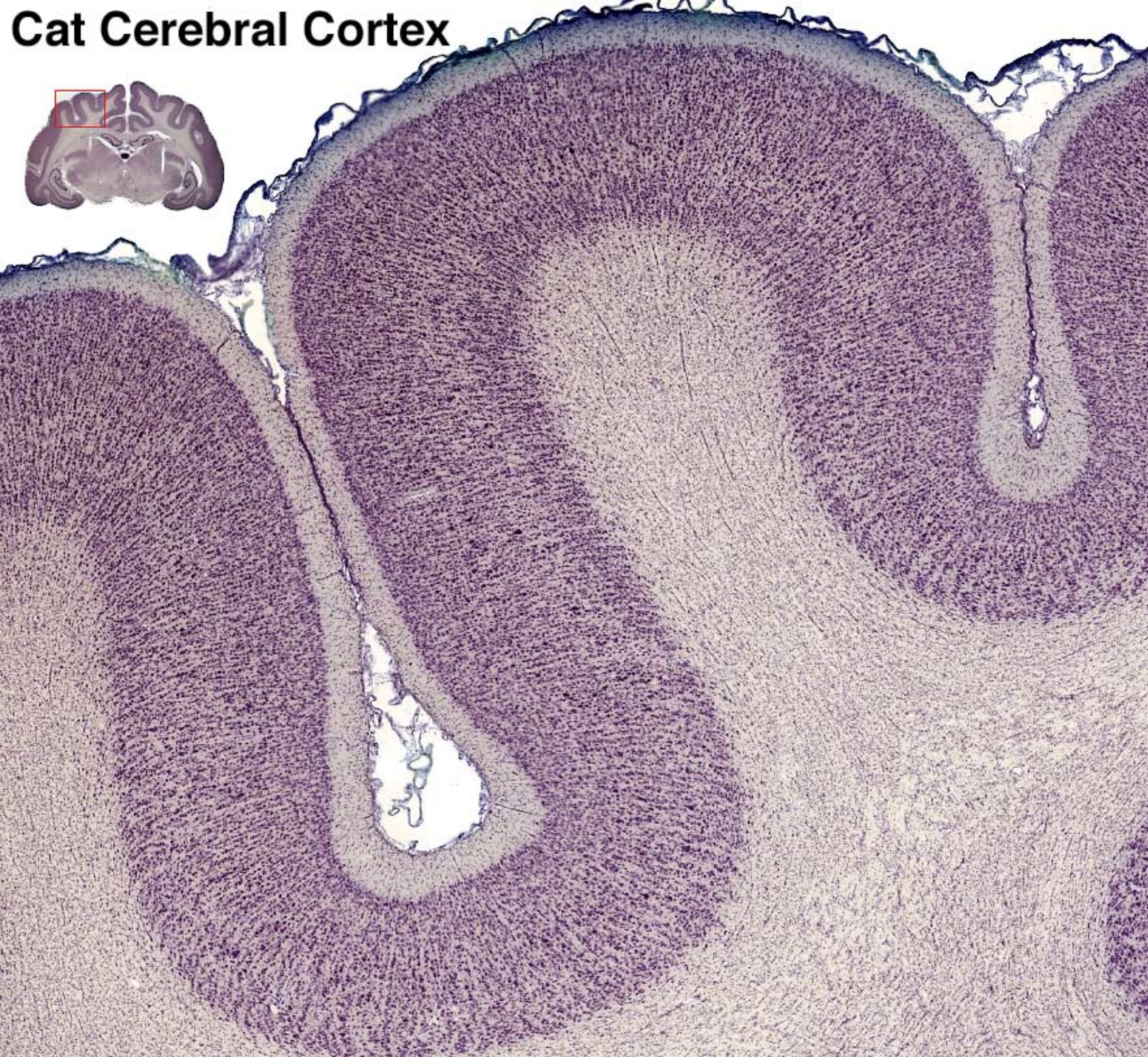
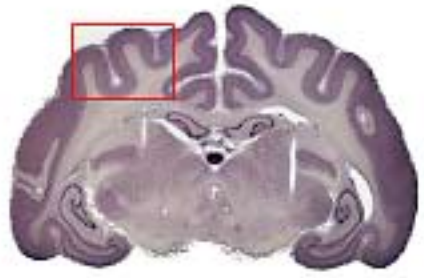- bilateral hollow outgrowths become right and left *cerebral hemispheres*; the cavity of each outgrowth forms a *lateral ventricle* that communicates with the third ventricle via an interventricular foramen (in the wall of each lateral ventricle, a choroid plexus develops that is continuous with a choroid plexus of the third ventricle via an interventricular foramen);
- at the midline, the rostral end of the telencephalon forms the rostral wall of the third ventricle (the wall is designated lamina terminalis);
- the mantle layer surrounding the lateral ventricle in each hemisphere gives rise to basal nuclei and *cerebral cortex*;
- cellular migrations that form cerebral cortex:
  - from the mantle layer, cells migrate radially to the surface of the cerebral hemisphere, guided by glial cells that extend from the ventricular surface to the outer surface of the cerebral wall (thus each locus of mantle gives rise to a specific area of cerebral cortex);
  - migration occurs in waves; the first wave (which becomes the deepest layer of cortex) migrates to the surface of the cortex; the second wave (which forms the next deepest layer of cortex) migrates to the cortical surface, passing through first wave neurons which are displaced to a deeper position; the third wave . . . etc. (the cerebral cortex has six layers).

Cell connections are established within the cerebral cortex as waves of newly arriving neurons migrate through populations of neurons that arrived earlier.

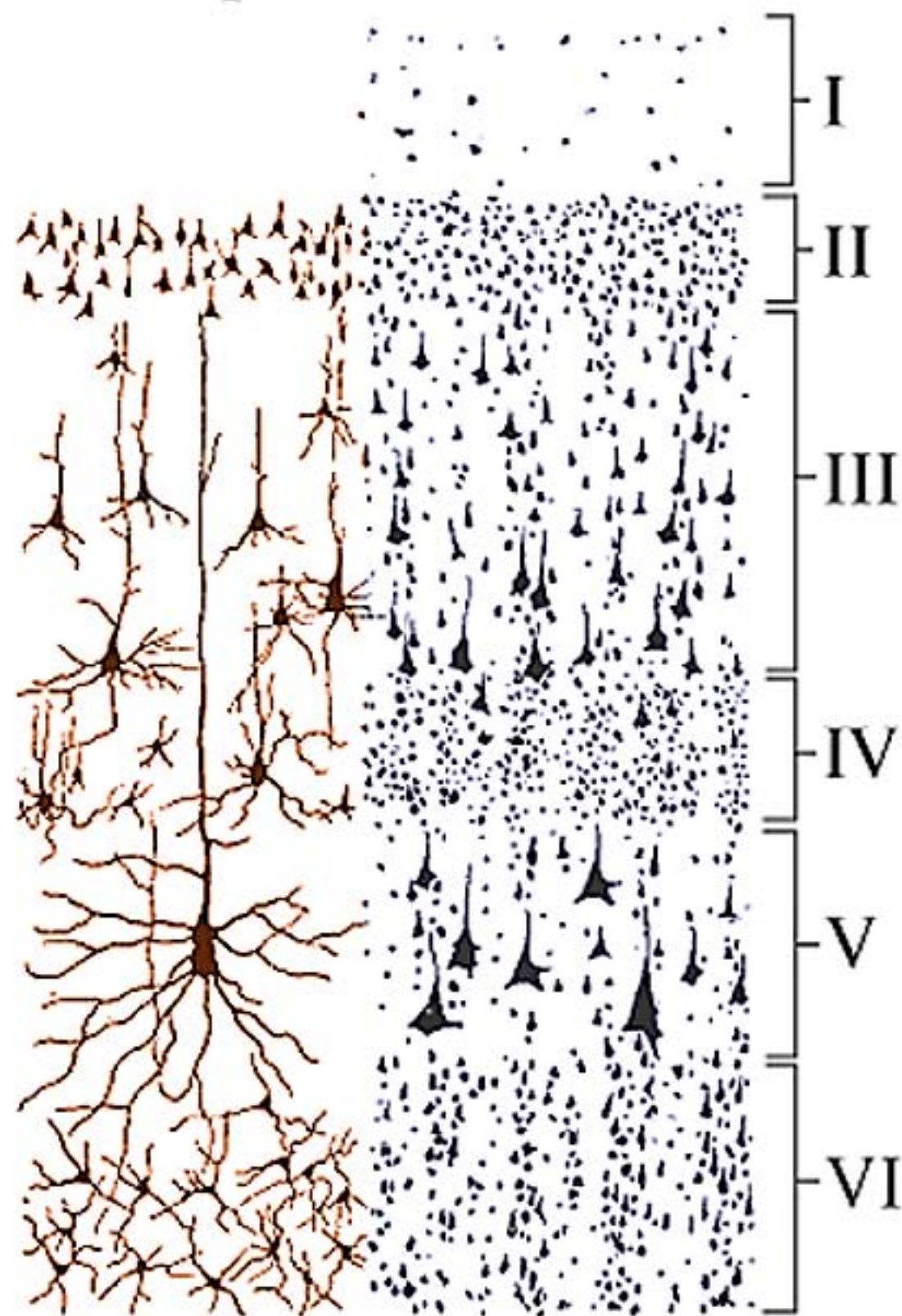
NOTE: Carnivores are born with a nervous system that does not mature until about six weeks postnatally (mature behavior is correspondingly delayed). In herbivores, the nervous system is close to being mature at birth.



# Cat Cerebral Cortex



— pia mater —



— white matter —



# Peripheral Nervous System

**NOTE:** • The peripheral nervous system (PNS) consists of **cranial and spinal nerves**. Nerve fibers within peripheral nerves may be classified as **afferent** (sensory) or **efferent** (motor) and as **somatic** (innervating skin and skeletal muscle) or **visceral** (innervating vessels and viscera). The visceral efferent (autonomic) pathway involves two neurons: 1] a preganglionic neuron that originates in the CNS and 2] a postganglionic neuron located entirely in the PNS. The **glial cell of the PNS** is the **neurolemmocyte** (Schwann cell).

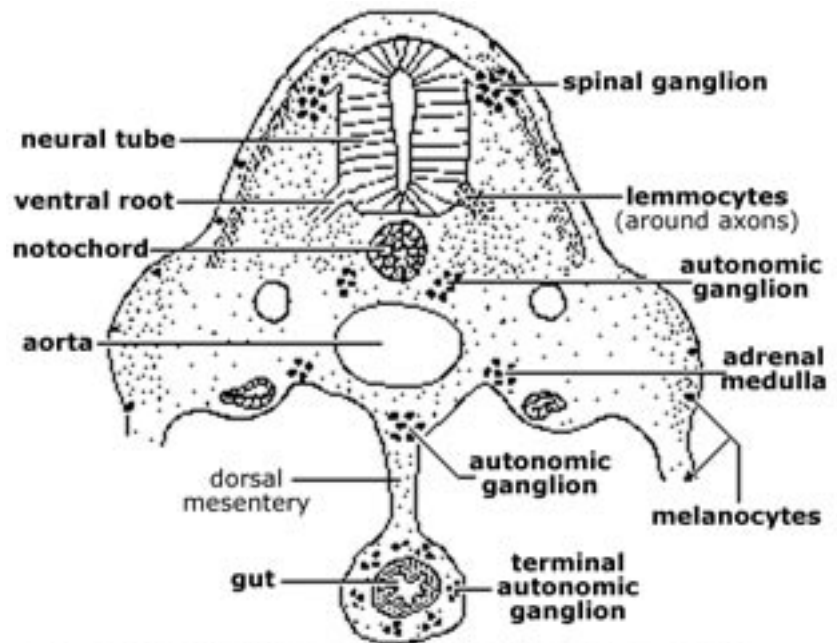
• All **afferent neurons** are **unipolar** and have their cell bodies in sensory ganglia, either **spinal ganglia** on dorsal roots or ganglia associated with cranial nerves. Somatic efferent and preganglionic visceral efferent neurons have their cell bodies located in the CNS, but their axons extend into the PNS. **Postganglionic visceral efferent neurons** have their cell bodies in **autonomic ganglia**.

– *neurolemmocytes* (Schwann cells) arise from **neural crest** and migrate throughout the PNS, ensheathing and myelinating axons and forming satellite cells in ganglia;

– *afferent neurons* originate from neural crest as bipolar cells that subsequently become unipolar; in the case of cranial nerves, afferent neurons also originate from placodes (placode = localized thickening of ectoderm in the head);

– *postganglionic visceral efferent neurons* arise from neural crest, the cells migrate to form autonomic ganglia at positions within the head, or beside vertebrae (along sympathetic trunk), or near the aorta, or in the gut wall (the latter are parasympathetic and come from sacral and hindbrain regions);

– *somatic efferent neurons* and *preganglionic visceral efferent neurons* arise from the basal plate of the neural tube; their cell bodies remain in the CNS and their axons join peripheral nerves;



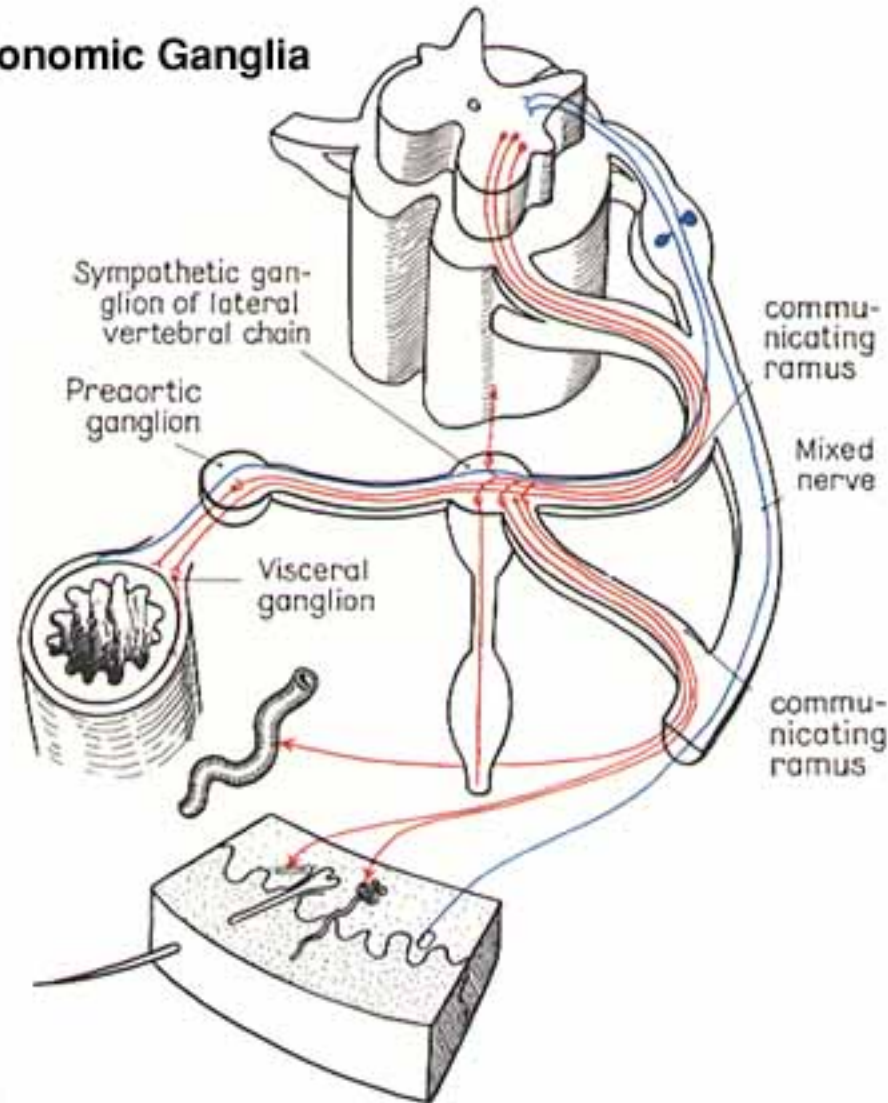
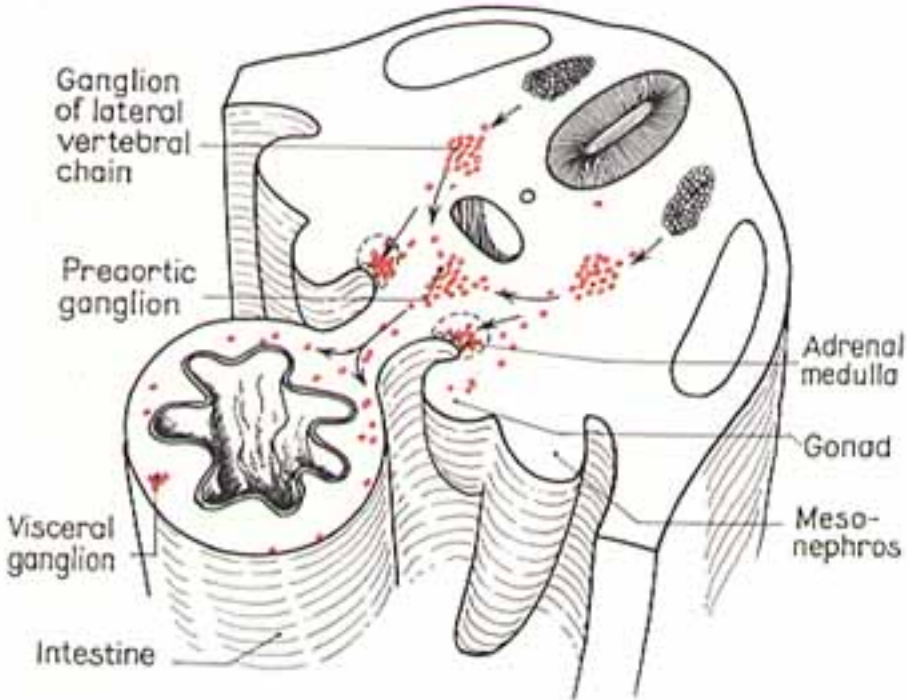
**Developing Peripheral Nervous System**

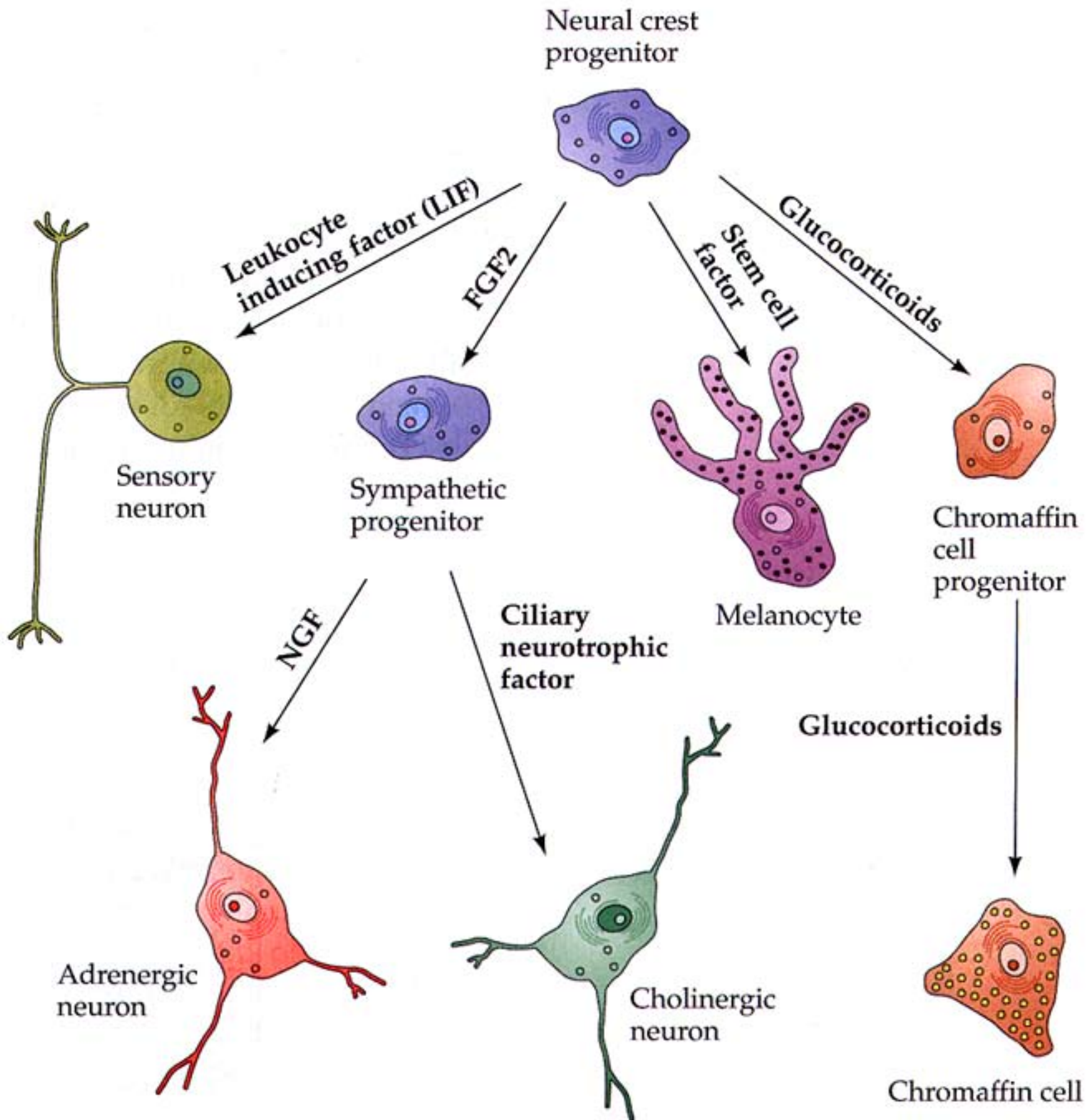
Peripheral nerves establish contact early with the nearest somite, somitomere, placode, or branchial arch and innervate derivatives of these embryonic structures.

Innervation continuity is retained even when the derivatives are considerably displaced or when other structures have obstructed the pathway. The early establishment of an innervation connection explains why some nerves travel extended distances and make detours to reach distant inaccessible targets. The foremost example is the recurrent laryngeal nerve which courses from the brainstem to the larynx via the thorax, because the heart migrates from the neck to the thorax pulling the nerve with it.



# Neural Crest Migration to form Spinal and Autonomic Ganglia





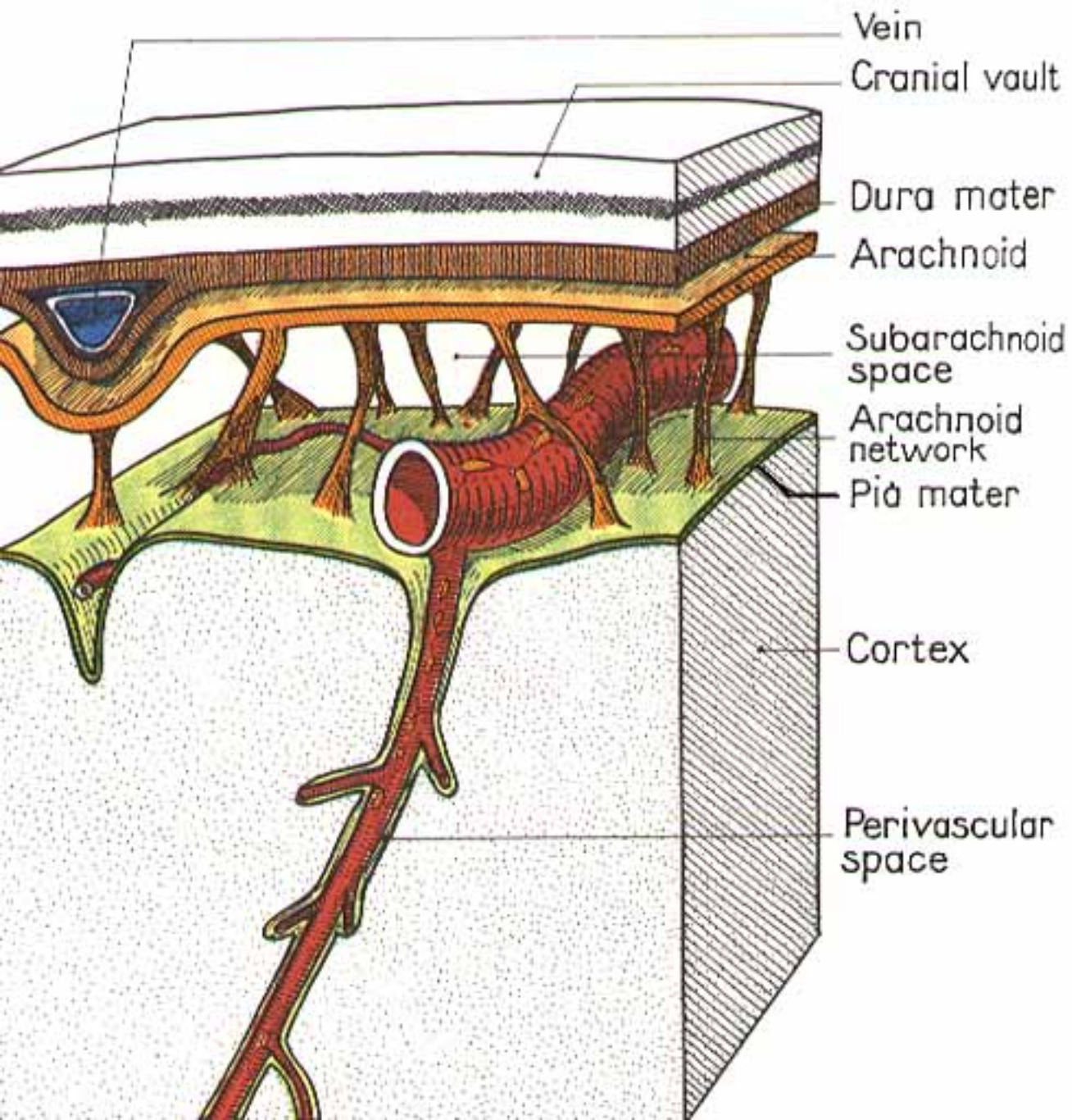
*Note:* Cranial nerves innervate specific branchial arches and their derivatives:  
trigeminal (V) - innervates first branchial arch (muscles of mastication)  
facial (VII) - innervates second branchial arch (muscles of facial expression)  
glossopharyngeal (IX) - innervates third branchial arch (pharyngeal muscles)  
vagus (X) - 4 & 6 branchial arches (muscles of pharynx, larynx, & esophagus)

## **Formation of Meninges**

Meninges surround the CNS and the roots of spinal and cranial nerves.

Three meningeal layers (dura mater, arachnoid, and pia mater) are formed as follows:

- mesenchyme surrounding the neural tube aggregates into two layers;
- the outer layer forms dura mater;
- cavities develop and coalesce within the inner layer, dividing it into arachnoid and pia mater; the cavity becomes the subarachnoid space which contains cerebrospinal fluid.



Vein

Cranial vault

Dura mater

Arachnoid

Subarachnoid space

Arachnoid network

Pia mater

Cortex

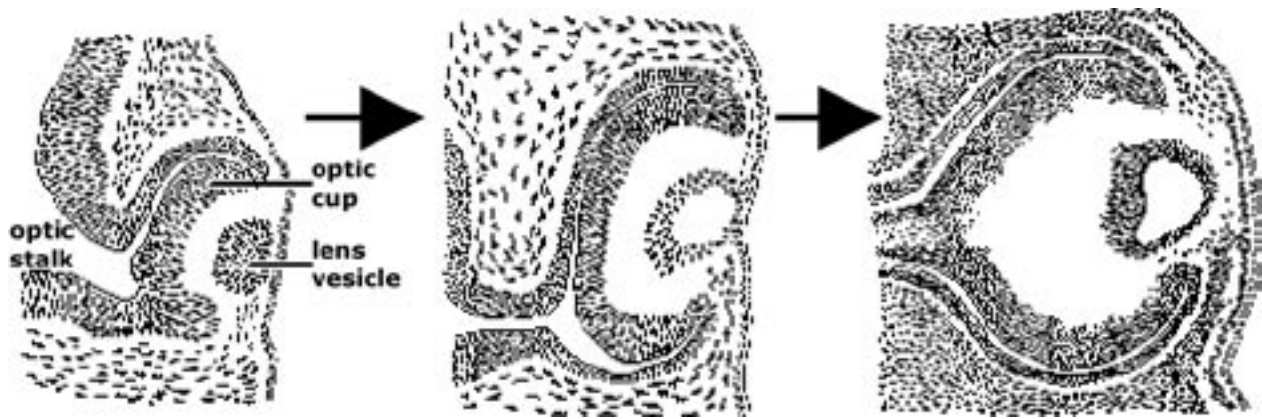
Perivascular space

# Special Senses

## Formation of the Eye

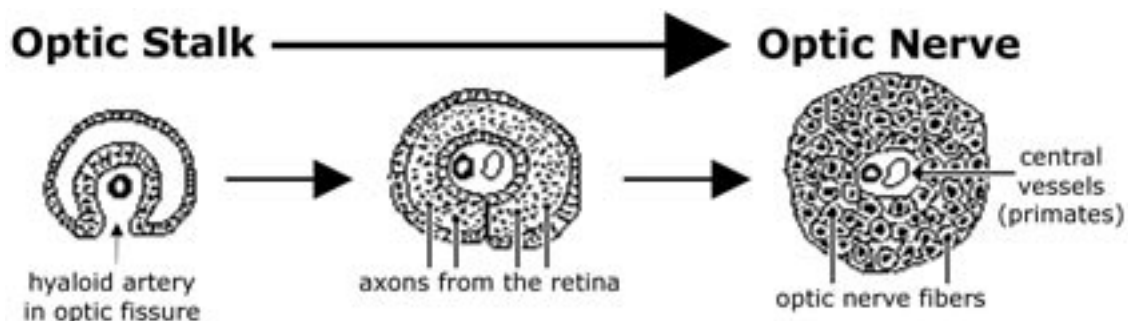
Both eyes are derived from a single field of the neural plate. The single field separates into bilateral fields associated with the diencephalon. The following events produce each eye:

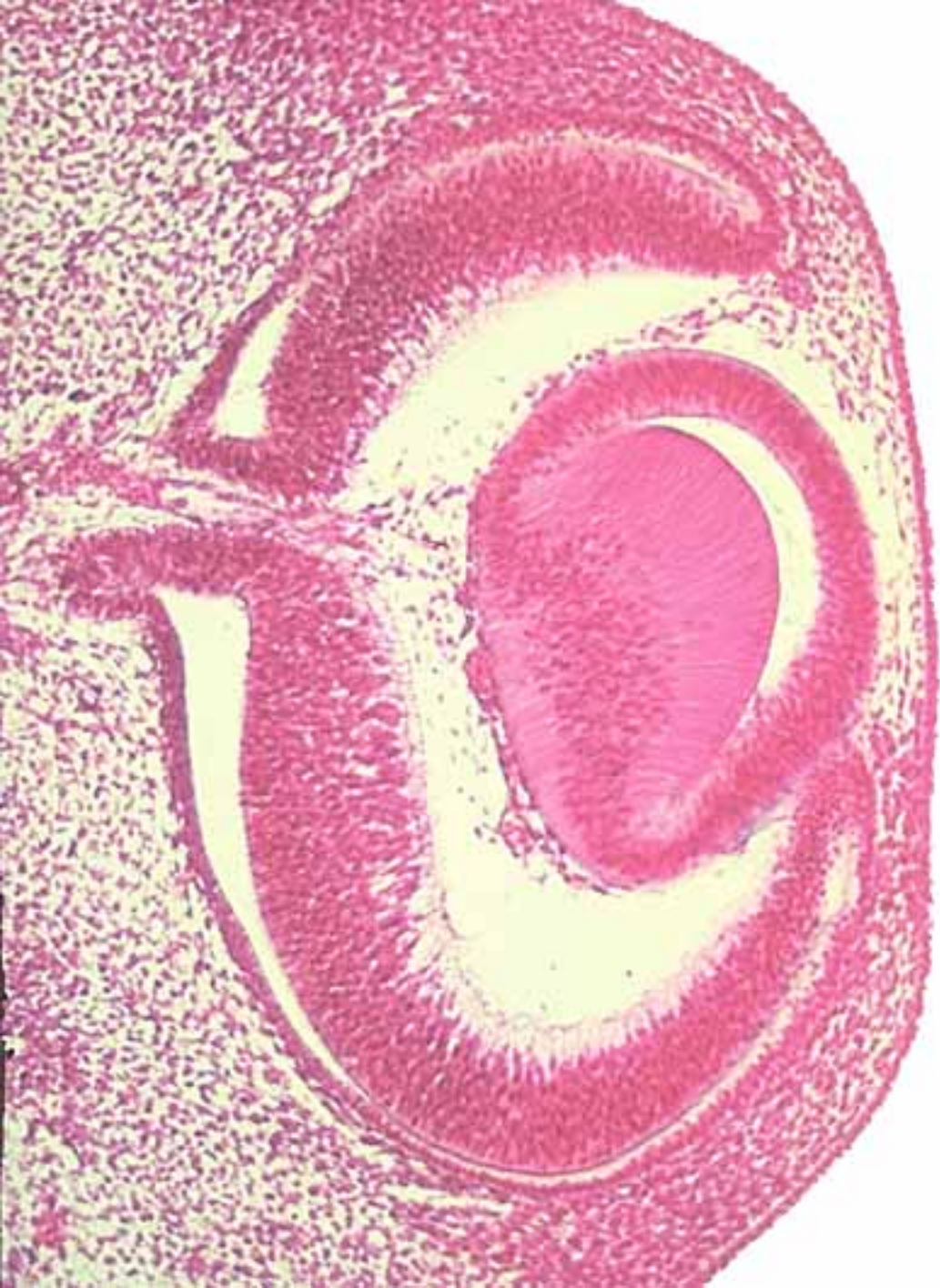- a lateral diverticulum from the diencephalon forms an *optic vesicle* attached to the diencephalon by an *optic stalk*;
- a *lens placode* develops in the surface ectoderm where it is contacted by the optic vesicle; the lens placode induces the optic vesicle to invaginate and form an **optic cup** while the placode invaginates to form a *lens vesicle* that invades the concavity of the optic cup;
- an *optic fissure* is formed by invagination of the ventral surface of the optic cup and optic stalk, and a *hyaloid artery* invades the fissure to reach the lens vesicle;



**NOTE:** The optic cup forms the *retina* and contributes to formation of the ciliary body and iris. The outer wall of the cup forms the outer pigmented layer of the retina, and the inner wall forms neural layers of the retina.

- The optic stalk becomes the *optic nerve* as it fills with axons traveling from the retina to the brain.
- The lens vesicle develops into the *lens*, consisting of layers of lens fibers enclosed within an elastic capsule.
- The vitreous compartment develops from the concavity of the optic cup, and the *vitreous body* is formed from ectomesenchyme that enters the compartment through the optic fissure.







— ectomesenchyme (from neural crest) surrounding the optic cup condenses to form inner and outer layers, the future *choroid* and *sclera*, respectively;

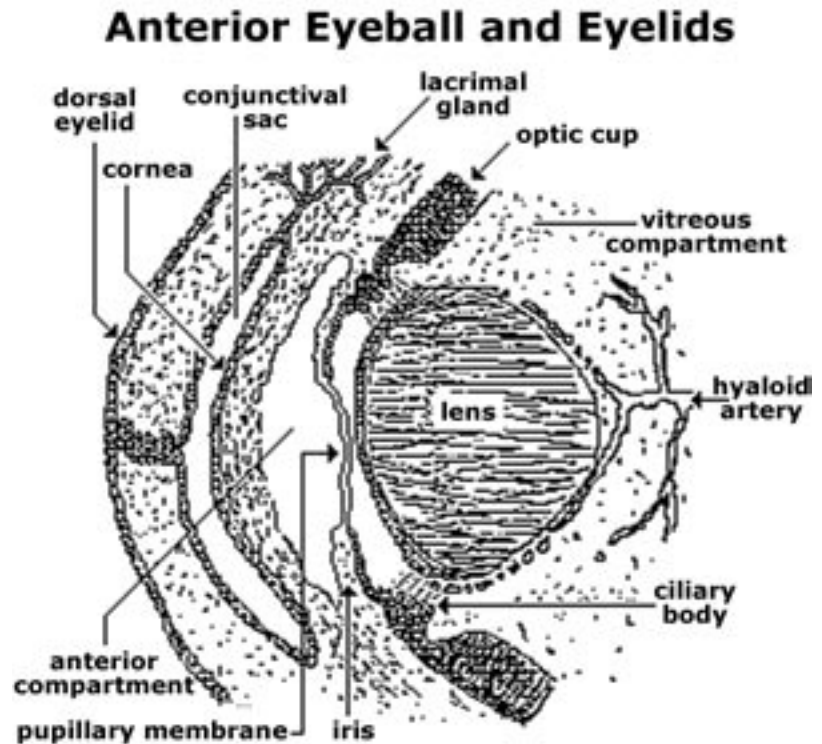
— the *ciliary body* is formed by thickening of choroid ectomesenchyme plus two layers of epithelium derived from the underlying optic cup; the ectomesenchyme forms ciliary muscle and the collagenous zonular fibers that connect the ciliary body to the lens;

— the *iris* is formed by choroid ectomesenchyme plus the superficial edge of the optic cup; the outer layer of the cup forms dilator and constrictor muscles and the inner layer forms pigmented epithelium; the ectomesenchyme of the iris forms a *pupillary membrane* that conveys an anterior blood supply to the developing lens; when the membrane degenerates following development of the lens, a pupil is formed;

— the *cornea* develops from two sources: the layer of ectomesenchyme that forms sclera is induced by the lens to become inner epithelium and stroma of the cornea, while surface ectoderm forms the outer epithelium of the cornea; the *anterior chamber* of the eye develops as a cleft in the ectomesenchyme situated between the cornea and the lens;

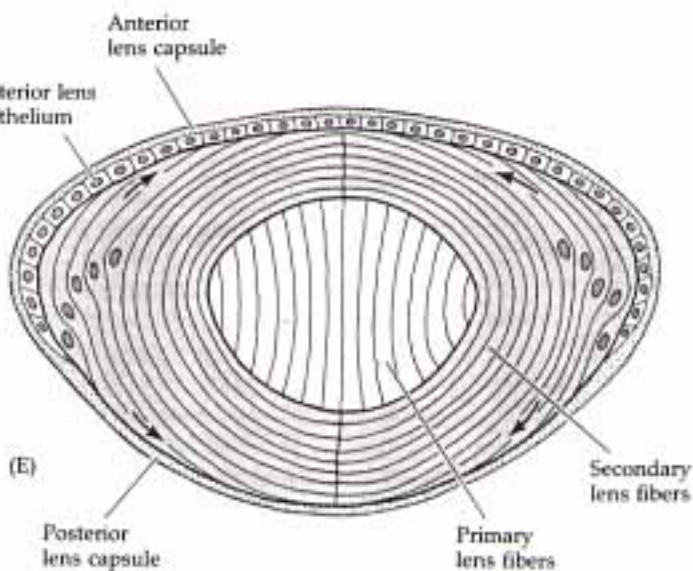
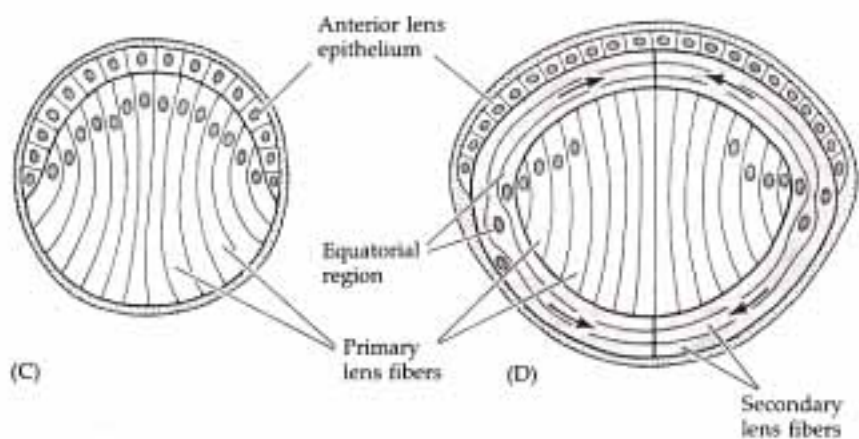
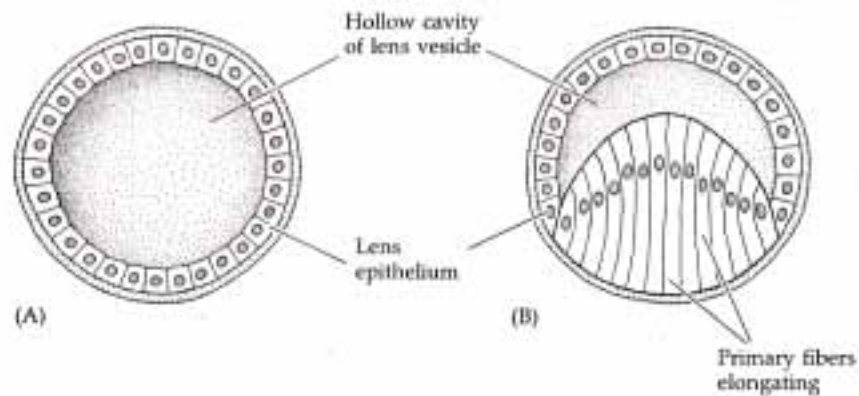
— the *eyelids* are formed by upper and lower folds of ectoderm, each fold includes a mesenchyme core; the folds adhere to one another but they ultimately separate either prenatally (ungulates) or approximately two weeks postnatally (carnivores); ectoderm lining the inner surfaces of the folds becomes *conjunctiva*, and *lacrimal glands* develop by budding of conjunctival ectoderm;

— skeletal muscles that move the eye (*extraocular eye mm.*) are derived from rostral somitomeres (innervated by cranial nerves III, IV, and VI).



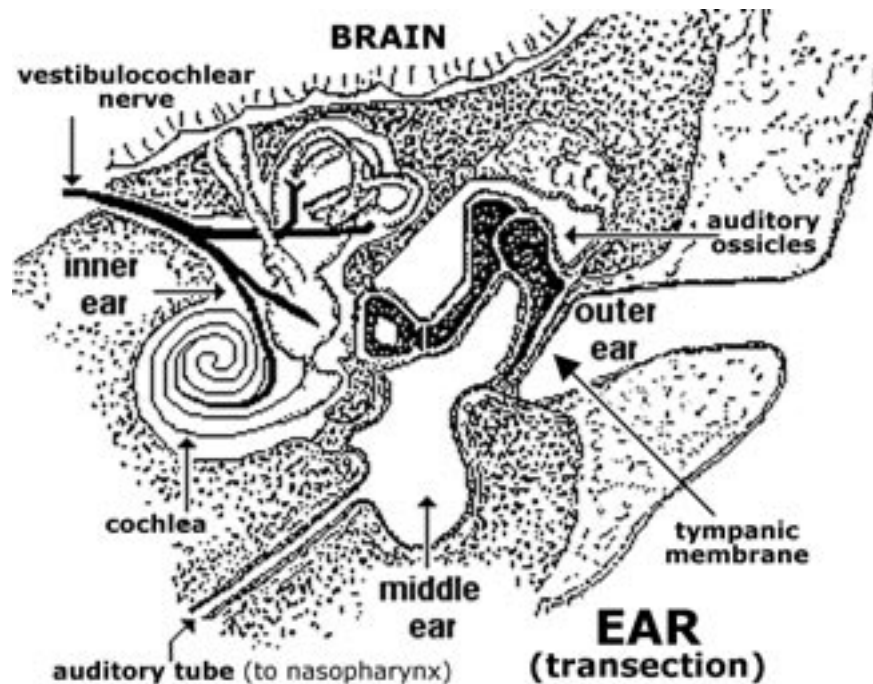
**Clinical considerations:**

- The ungulate retina is mature at birth, but the carnivore retina does not fully mature until about 5 weeks postnatally.
- Retinal detachment occurs between the neural and outer pigmented layers of the retina (inner and outer walls of the optic cup) which do not fuse but are held apposed by pressure of the vitreous body.
- Coloboma is a defect due to failure of the optic fissure to close.
- Microphthalmia (small eye) results from failure of the vitreous body to exert sufficient pressure for growth, often because a coloboma allowed vitreous material to escape.
- Persistent pupillary membrane results when the pupillary membrane fails to degenerate and produce a pupil.



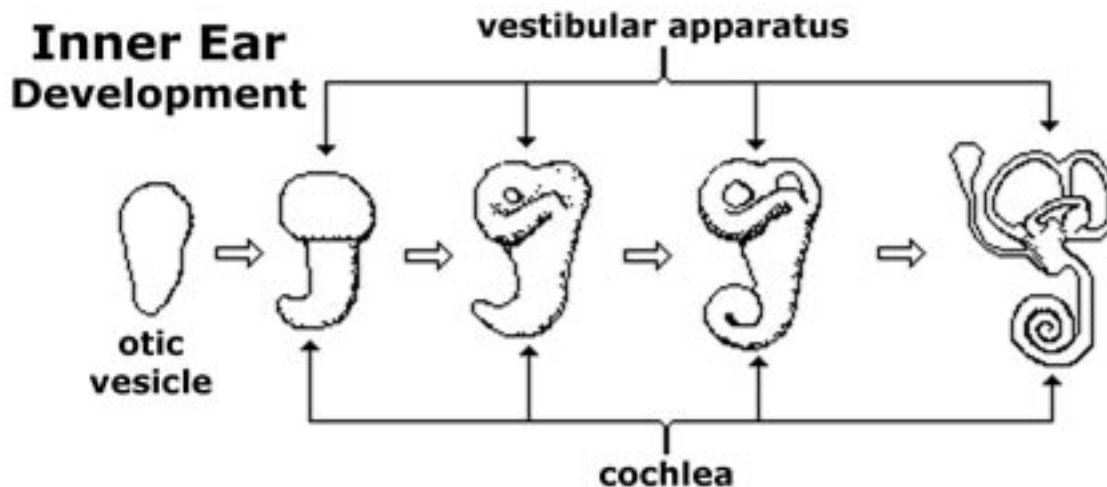
## Formation of the Ear

The ear has three components: external ear, middle ear, and inner ear. The *inner ear* contains sense organs for hearing (cochlea) and detecting head acceleration (vestibular apparatus), the latter is important in balance. Innervation is from the cochlear and vestibular divisions of the VIII cranial nerve. The *middle ear* contains bones (ossicles) that convey vibrations from the tympanic membrane (ear drum) to the inner ear. The *outer ear* channels sound waves to the tympanic membrane.



### Inner ear:

- an *otic placode* develops in surface ectoderm adjacent to the hindbrain; the placode invaginates to form a cup which then closes and separates from the ectoderm, forming an *otic vesicle* (otocyst); an *otic capsule*, composed of cartilage, surrounds the otocyst;
- some cells of the placode and vesicle become neuroblasts and form afferent neurons of the vestibulocochlear nerve (VIII);
- the otic vesicle undergoes differential growth to form the cochlear duct and semicircular ducts of the membranous labyrinth; some cells of the labyrinth become specialized receptor cells found in maculae and ampullae;
- the cartilagenous otic capsule undergoes similar differential growth to form the osseous labyrinth within the future petrous part of the temporal bone.



### **Middle ear:**

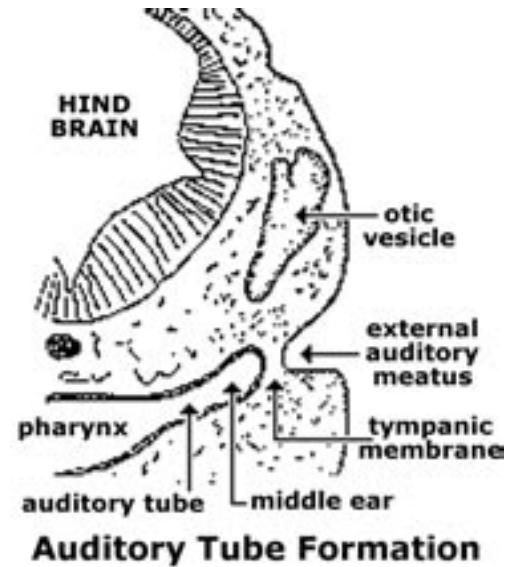
— the dorsal part of the *first pharyngeal pouch* forms the lining of the auditory tube and tympanic cavity (in the horse a dilation of the auditory tube develops into the guttural pouch);

— the malleus and incus develop as endochondral bones from ectomesenchyme in the first branchial arch and the stapes develops similarly from the second arch (in fish, these three bones have different names; they are larger and function as jaw bones).

### **Outer ear:**

— the tympanic membrane is formed by apposition of endoderm and ectoderm where the first pharyngeal pouch is apposed to the groove between the first and second branchial arches;

— the external ear canal (meatus) is formed by the groove between the first and second branchial arches; the arches expand laterally to form the wall of the canal and the auricle (pinna) of the external ear.



### **Taste buds**

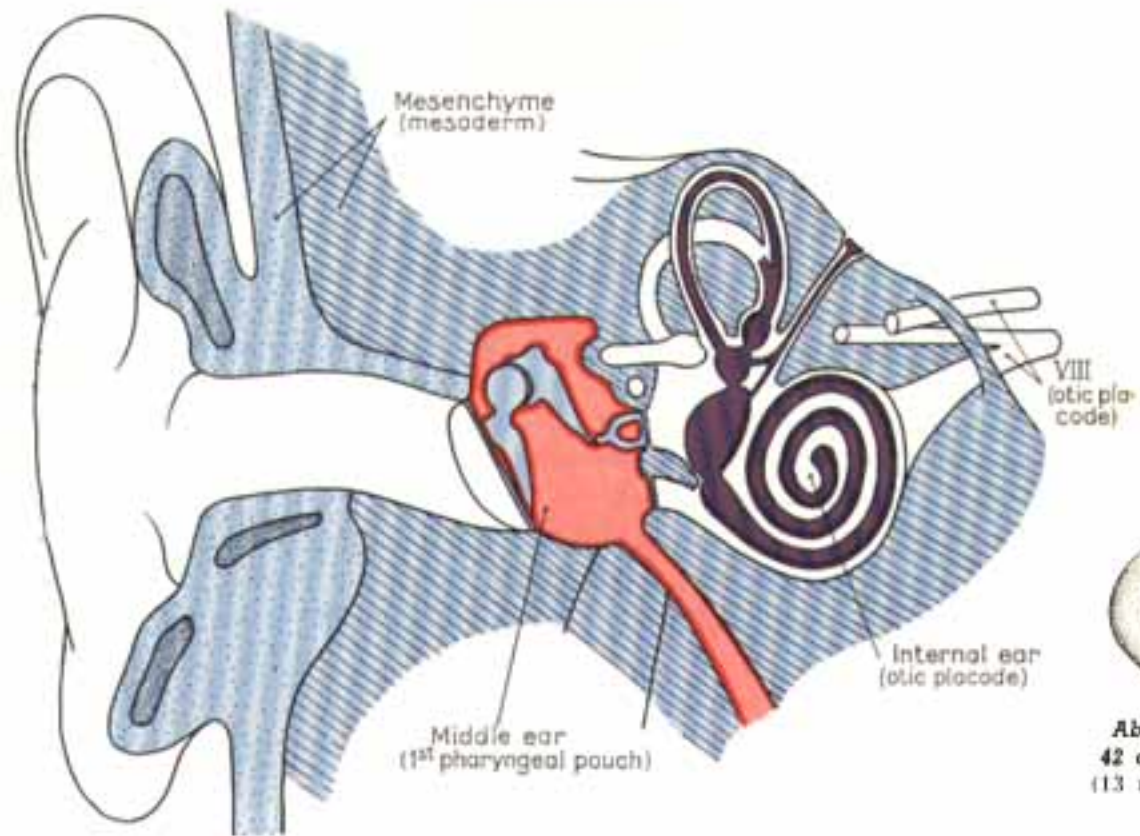
Taste buds are groups of specialized (chemoreceptive) epithelial cells localized principally on papillae of the tongue. Afferent innervation is necessary to induce taste bud formation and maintain taste buds. Cranial nerves VII (rostral two-thirds of tongue) and IX (caudal third of tongue) innervate the taste buds of the tongue.

### **Olfaction**


Olfaction (smell) involves olfactory mucosa located caudally in the nasal cavity and the vomeronasal organ located rostrally on the floor of the nasal cavity. Olfactory neurons are chemoreceptive; their axons form olfactory nerves (I).

— an olfactory (nasal) placode appears bilaterally as an ectodermal thickening at the rostral end of the future upper jaw; the placode invaginates to form a nasal pit that develops into a nasal cavity as the surrounding tissue grows outward; in the caudal part of the cavity, some epithelial cells differentiate into olfactory neurons;

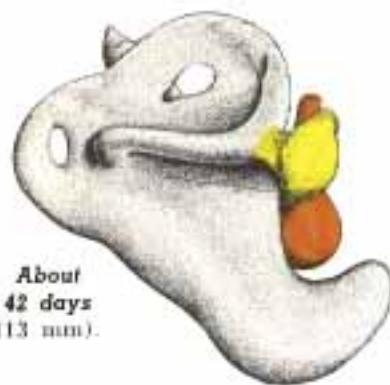
— the vomeronasal organ develops as an outgrowth of nasal epithelium that forms a blind tube; some epithelial cells of the tube differentiate into chemoreceptive neurons.



About 36 days (9 mm).



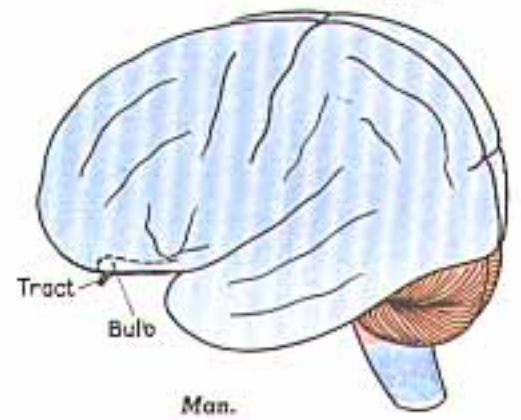
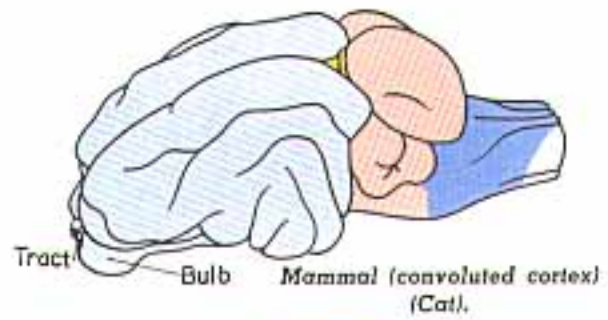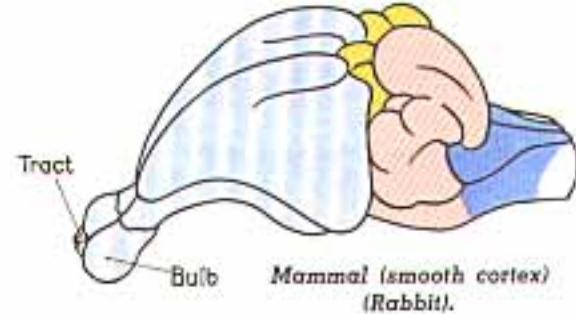
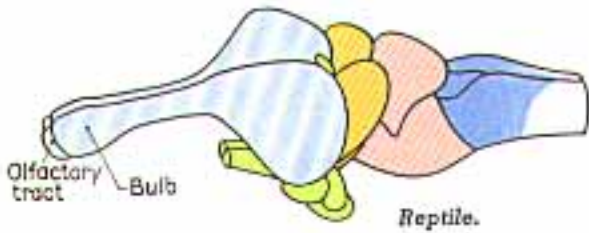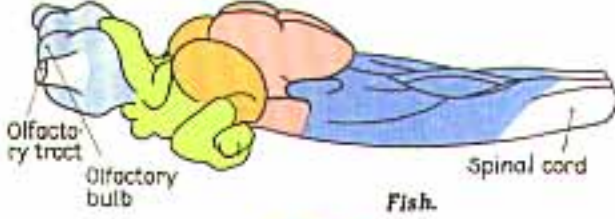About 50 days (20 mm).

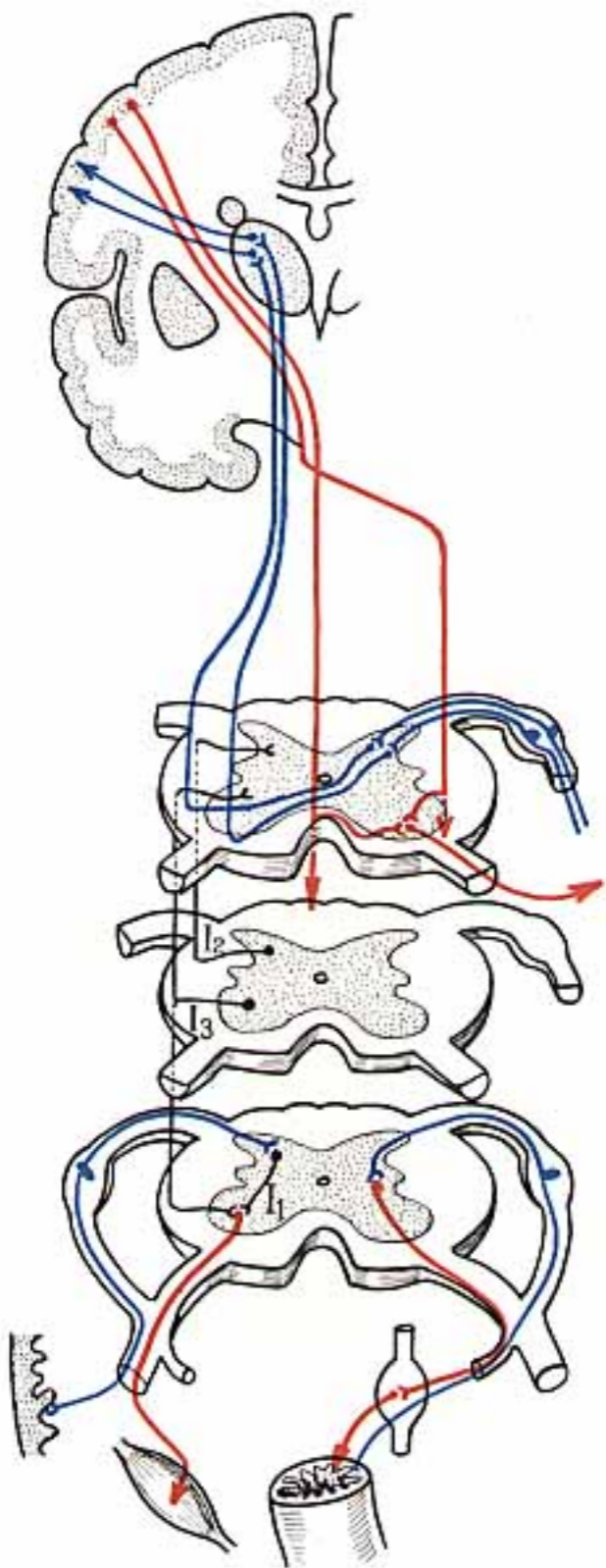


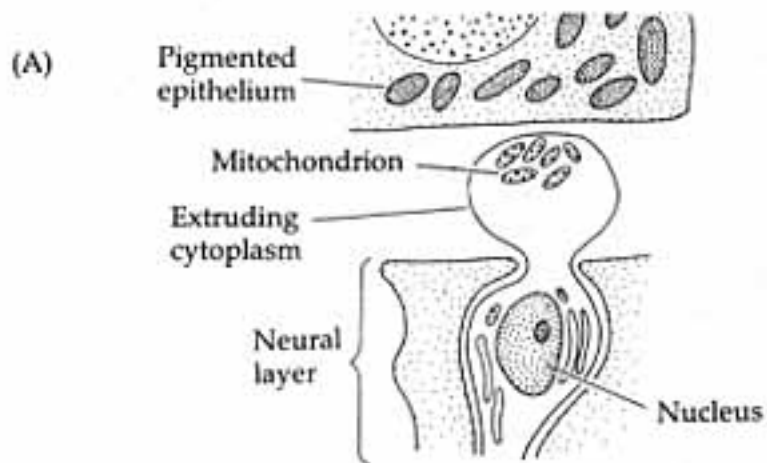
About 42 days (13 mm).



About 60 days (30 mm).







**FIGURE 28**

Differentiation of the photoreceptive apparatus in a rod or cone cell. (A) Cells extrude a bulb of cytoplasm into the space between the neural and pigmented layers of the retina. (B) The bulb expands and forms a cytoplasmic region and a region of stacked membranes, supported by a nonmotile cilium (axial filament). (C) The membranes become internalized and the photoreceptive pigments become localized to these regions. (After Coulombre, 1965.)

